

LATE AND VERY LATE STENT THROMBOSIS IN THE ERA OF SECOND-GENERATION DRUG-ELUTING STENTS

Jaya Mallidi, *Amir Lotfi

Division of Cardiology, Baystate Medical Center, Tufts University, Springfield, Massachusetts, USA

*Correspondence to amir.lotfi@bhs.org

Disclosure: The authors have declared no conflicts of interest.

Received: 24.11.15 **Accepted:** 10.03.16

Citation: EMJ. 2016;1[3]:85-93.

ABSTRACT

Stent thrombosis is a life-threatening complication of percutaneous coronary intervention that often results in ST-segment myocardial infarction or sudden cardiac death. First-generation drug-eluting stents (DESs) are associated with an increased risk of late and very late stent thrombosis compared with bare-metal stents due to delayed endothelialisation of the stent struts. The second-generation DES design includes a number of improved features (thinner stent struts, fluorinated copolymers, and different anti-proliferative agents) to decrease the risk of late stent thrombosis. Currently, the cobalt-chromium everolimus-eluting stent, a second-generation stent, has the lowest risk of stent thrombosis when compared with the available alternatives. Given the improved design of second-generation stents, a shorter duration of dual antiplatelet therapy of 6 months may be enough to reduce the rate of bleeding complications without increasing the risk of adverse cardiovascular events. Future large-scale randomised trials are required to evaluate the safety and efficacy of third-generation DESs which feature bioresorbable polymers and scaffolds.

Keywords: Stent thrombosis, drug-eluting stent (DES).

INTRODUCTION

Percutaneous coronary intervention (PCI) is a common procedure performed worldwide as part of the treatment for coronary artery disease. In the UK alone, 92,589 PCIs were performed in 2013 (1,444 per million annually), with drug-eluting stents (DESs) used in 82% of PCIs performed.¹ While the first-generation DESs (Cypher[®] sirolimus-eluting stents [C-SES] and Taxus[®] paclitaxel-eluting stents [PESs]) significantly reduced the restenosis rates compared with bare-metal stents (BMSs),² there was concern regarding the resulting increased rate of late and very late stent thrombosis.^{3,4}

Stent thrombosis is a potentially life-threatening complication of PCI that often causes acute closure of the vessel and, as a result, can cause ST-segment elevation myocardial infarction or sudden cardiac death. Despite rapid access to PCI, stent thrombosis is associated with a high 30-day mortality rate of 10-25%.⁵ Though a rare complication, given the large number of PCIs performed annually, the absolute number of patients with stent thrombosis

is substantial. The concern relating to risk of late stent thrombosis with first-generation DESs prompted the development of second-generation DESs using different drugs (everolimus or zotarolimus), different stent platforms (thinner stent struts), and a more biocompatible polymer. This article will summarise the existing literature regarding the relative risk of stent thrombosis with second-generation DESs and review the optimal duration of dual antiplatelet therapy (DAPT) to reduce the risk of stent thrombosis in the era of second-generation DESs.

Definition of Stent Thrombosis

In order to standardise the definition of stent thrombosis, the Academic Research Consortium (ARC) was formed in 2007 as part of a collaborative effort between the academic research organisations in the USA and Europe.⁶ Stent thrombosis was categorised based on the certainty of evidence from angiographic and pathological data as 'definite' (confirmed by angiography in addition to clinical or pathological acute coronary

syndrome), 'probable' (any unexplained death ≤ 30 days after stent placement or myocardial infarction documented in a territory of the implanted stent without angiographic confirmation), or 'possible' (unexplained death ≤ 30 days of intracoronary stenting). Based on the timing of occurrence, stent thrombosis can be classified as acute (≤ 24 hours), sub-acute (between 24 hours and 30 days), late (30 days–1 year), and very late (≥ 1 year).⁶

Mechanism and Pathophysiology of Late Stent Thrombosis

The pathophysiology of late stent thrombosis in first-generation DESs is related to chronic inflammation, persistent fibrin deposition, and delayed arterial healing, resulting in incomplete endothelialisation of the stent struts into the arterial wall.⁷ First-generation DESs are covered with potent anti-proliferative agents such as sirolimus and paclitaxel. These drugs impede the smooth muscle cell proliferation, suppress neointimal formation, and delay the normal healing process of the injured arterial wall.⁷ Hence, the percentage of uncovered stent struts exposed directly to the blood stream and serving as a nidus for thrombus formation, is higher after implantation of DESs.

In order to determine the pathological correlates of late stent thrombosis, Finn et al.⁸ studied 62 coronary lesions from 46 human autopsy cases with first-generation DESs implanted for >30 days. Endothelial coverage was noted as the most significant histological predictor of stent thrombosis.⁸ The average stent length without neointimal coverage was significantly higher in thrombosed DESs lesions.⁸ The odds ratio (OR) for thrombosis was 9.0 (95% confidence interval [CI]: 3.5–22.0) for a stent with $>30\%$ uncovered struts compared with a stent with complete coverage.⁸

Incomplete, non-uniform healing of the injured arterial wall following DES implantation is triggered by several factors: lesion characteristics, drug properties, total drug dose, drug release profile and distribution, and polymer biocompatibility.⁷ In a study of 127 patients with sirolimus or paclitaxel coated stents who died >30 days after implantation, incomplete stent strut coverage was more frequently noted in stents deployed in bifurcation lesions, bypass grafts, restenosed lesions, chronic total occlusions, left main lesions, or lesions >30 mm.⁹

In summary, the underlying mechanism of late stent thrombosis after DES implantation relates

to delayed arterial healing, chronic inflammation, fibrin deposition, and impaired endothelialisation of the stent struts. However, the final triggering event is governed by multiple factors including lesion type, the drug, and stent characteristics as described above.

Features of Second-Generation Drug-Eluting Stents Contributing to Decreased Risk of Late Stent Thrombosis

Second-generation DESs have been designed with specific features to overcome the issue of delayed endothelialisation noted with first-generation DESs (Figure 1). The current US Food and Drug Administration (FDA)-approved DESs with specific design features are listed in Figure 2.

Thinner stent struts

Second-generation stents have thinner stent struts (81–91 μm) compared with the first-generation stents (100–140 μm). In a study of 72 patients with *de novo* lesions undergoing DESs implantation, using optical coherence tomography, Tada et al.¹⁰ showed that the number of uncovered struts was significantly higher with thick strut DESs than with thin strut DESs at 6–8 months. In another study using *ex vivo* flow set up to study device thrombogenicity, Kolandaivelu et al.¹¹ demonstrated that thicker stent struts were 49% more thrombogenic as they caused flow disruption and stagnation. In order to reduce strut thickness while preserving the radial strength and radio opacity of the stents, newer alloys were used in second-generation DESs (chromium cobalt: Xience V[®], Xience Prime[™], Endeavor[®], and Resolute[™]; and platinum chromium: Promus Element[®]) instead of the stainless steel used in first-generation DESs.

Fluorinated copolymer

Hypersensitivity reactions to non-erodible polymers used in first-generation DESs (poly[ethylene-co-vinyl acetate] and poly-n-butyl methacrylate in the Cypher stent, and poly[styrene-3-isobutylene-8-styrene] in the Taxus stent) resulted in chronic inflammation with eosinophil deposition, causing delayed healing and late or very late stent thrombosis.^{7,12–14} More biocompatible polymers (e.g. fluorinated copolymer consisting of vinylidene fluoride and hexafluoropropylene in Xience everolimus-eluting stents [EESs], and phosphorylcholine in Endeavor zotarolimus-eluting stents [E-ZES]) are used in second-generation DESs to decrease the hypersensitivity

response.^{7,15-17} In an autopsy study consisting of 204 lesions, the cobalt-chromium everolimus-eluting stent (CoCr-EES) showed a lower inflammation score with no hypersensitivity, decreased fibrin deposition, and a lower rate of late and very late stent thrombosis compared with SESs and PESs.¹⁴

Difference in anti-proliferative drugs

The first-generation DESs used either sirolimus (also known as rapamycin) or paclitaxel as the anti-proliferative agent. Sirolimus is a macrolide antibiotic that binds to FK506-binding protein 12 and blocks the mammalian target of rapamycin.¹⁶ The G1/S phase transition in the cell cycle is

blocked, resulting in inhibition of smooth muscle migration and proliferation. Paclitaxel inhibits the mitotic process, blocking the transition from G2 to G1 phase by stabilising the microtubules and preventing depolymerisation.¹⁶

The second-generation stents use different anti-proliferative agents: everolimus (Xience V, Xience Prime, and Promus Element) and zotarolimus (Endeavor and Resolute). Everolimus is a hydroxyethyl derivative of sirolimus and has a similar mechanism of action.¹⁶ However, the dose of everolimus used in the CoCr-EES is lower than that of sirolimus (88 µg for a 3.0x18.0 mm stent versus 150 µg of sirolimus for the same stent).¹⁷

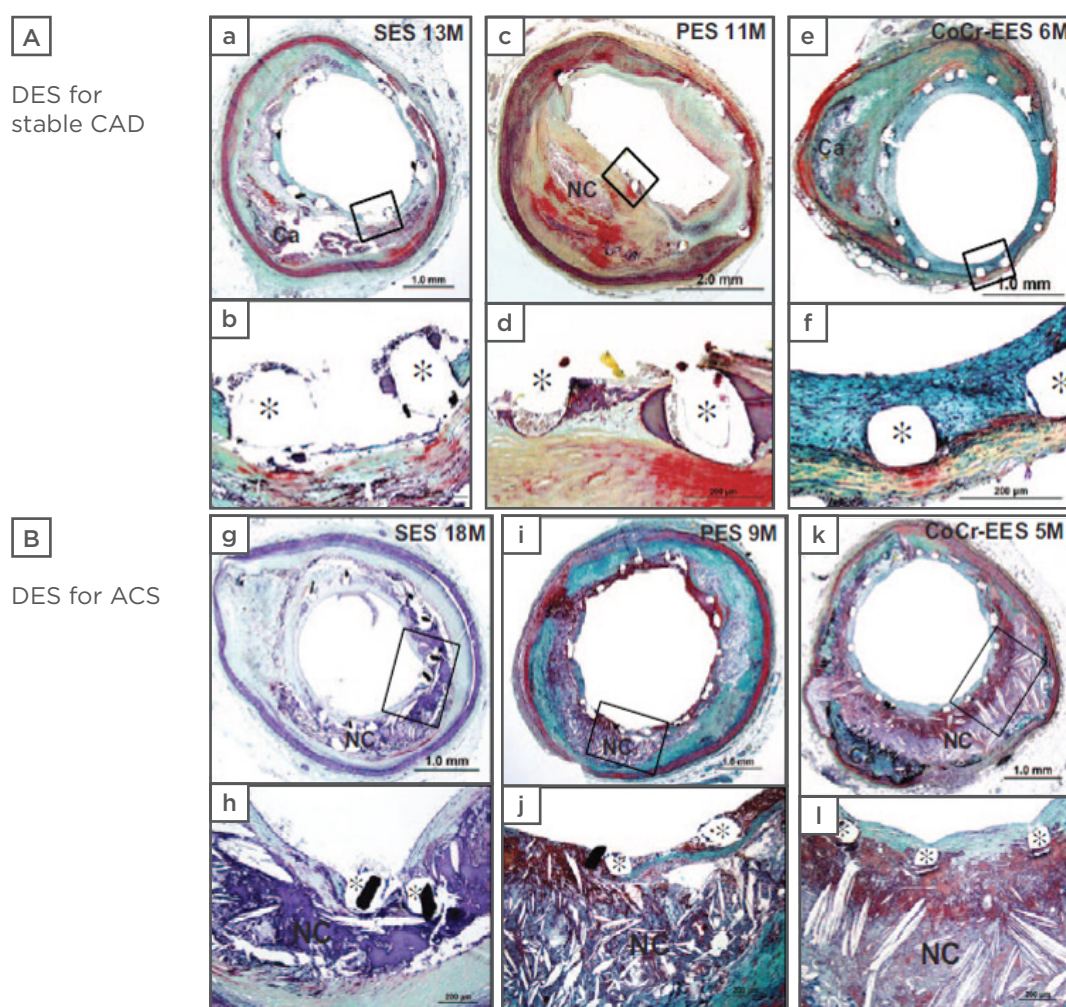


Figure 1: Histopathology comparing first and second-generation drug-eluting stents.

Representative images of sirolimus-eluting stents (SESs), paclitaxel-eluting stents (PESs), and cobalt-chromium everolimus-eluting stents (CoCr-EESs) implanted for: A (a-f): stable coronary artery disease (CAD); and B (g-l): acute coronary syndrome (ACS). Histology sections from:

(a, b): a 53-year-old patient with an SES implanted in the proximal left anterior descending coronary artery at 13 months. a) Low power image showing mild neointimal growth and underlying fibrocalcific plaque. b) High power image showing focal uncovered struts.

(c, d): a 71-year-old man with a PES implanted in the right coronary artery 11 months *antemortem*. c) Low power image showing mild-to-moderate neointimal proliferation and underlying fibroatheroma. d) High power image showing uncovered struts with persistent peri-strut fibrin deposition shown.

(e, f): a 60-year-old man who received a CoCr-EES in the mid left circumflex artery 6 months *antemortem*. e) A low power image showing mild neointimal proliferation and underlying fibrocalcific plaque. All struts are covered with proteoglycan-rich neointima with absence of fibrin, highlighted in f), a high-power image.

(g, h): a 74-year-old woman who received a SES in the proximal left anterior descending coronary artery for acute myocardial infarction 18 months *antemortem* and died of diffuse severe CAD. g) A low-power image showing mild neointimal proliferation with h) focal uncovered struts and strut penetration into the necrotic core (NC).

(i, j): a 64-year-old woman with a PES implanted in the right coronary artery for acute myocardial infarction 9 months *antemortem* who died of congestive heart failure. i) A low power image shows patent lumen with stent struts surrounded by fibrin and an underlying NC. j) Uncovered struts with fibrin deposition that overlies the NC.

(k, l): a 67-year-old man who received a CoCr-EES in the proximal left anterior descending coronary artery for non-ST segment elevation acute myocardial infarction 5 months *antemortem* who died of non-cardiac causes. k) A low-power image showing mild neointimal proliferation and an underlying large NC.

All struts are covered with a thin neointima overlying the NC, highlighted in the high-power image in l).

Histological sections stained with Movat pentachrome.

*Stent strut.

DES: drug-eluting stent.

Used with permission, taken from Otsuka F et al.¹⁴

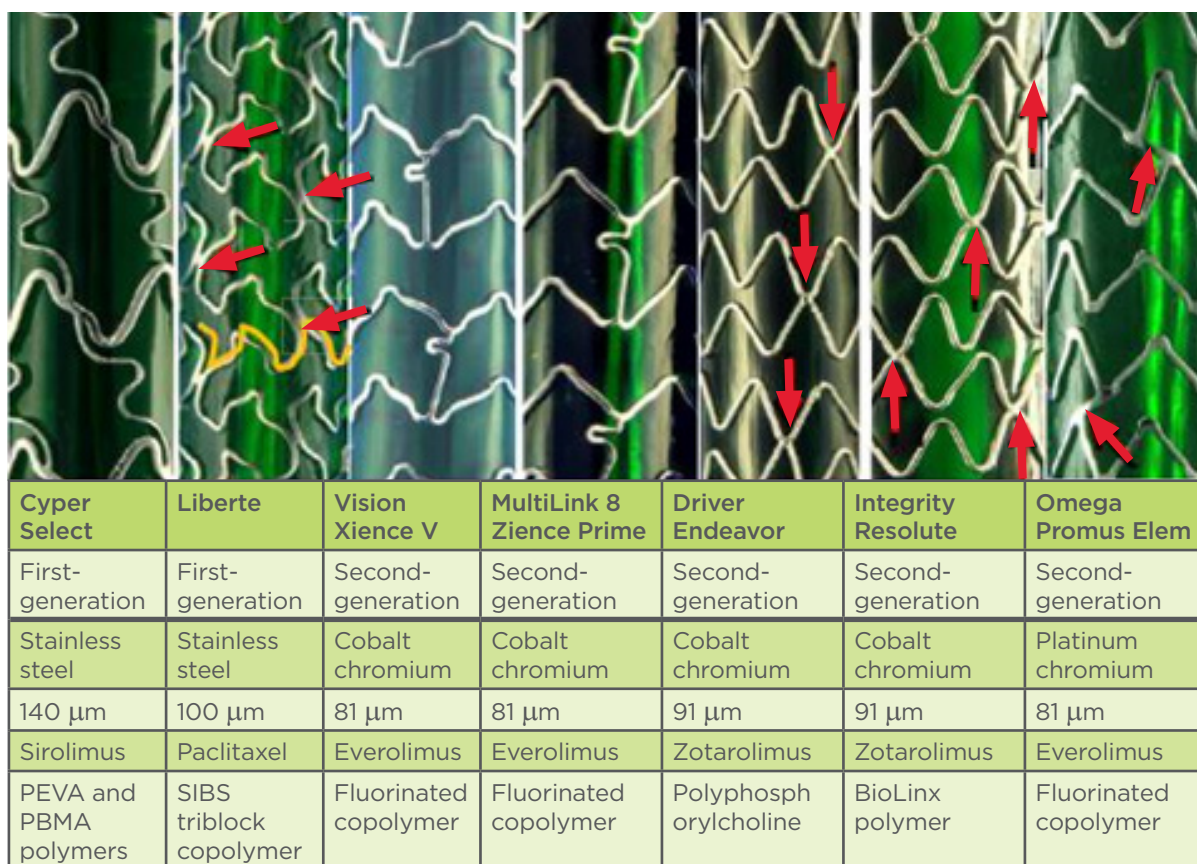


Figure 2: Comparison of various features of currently approved drug-eluting stents.

Photographs of stent designs and names and the metal they are constructed from, strut thickness in microns, anti-proliferative agent, and the polymer used in each stent. Red arrows represent the welds between the sinusoidal hoops of the stent struts.

PEVA: poly(ethylene-vinyl acetate); PBMA: poly(butyl methacrylate); SIBS: styrene-b-isobutylene-b-styrene.

Modified from Ormiston JA et al.⁵³

Zotarolimus is a semisynthetic derivative of sirolimus in which the tetrazole group has replaced the hydroxyl group, making it more lipophilic and enhancing the absorption of the drug across the cell membrane.¹⁶ These differences in the type of anti-proliferative agent, drug load, and kinetics may also contribute to the reduced rates of late stent thrombosis seen in second-generation DESs.¹⁸

Clinical Trials Comparing Second-Generation Drug-Eluting Stents with First-Generation Drug-Eluting Stents and Bare-Metal Stents

Everolimus-eluting stents

In a meta-analysis of the 3-year results from the SPIRIT II, III, and IV clinical trials, the rate of stent thrombosis was significantly lower with EESs compared with PESs (0.7% versus 1.7%, $p=0.003$).¹⁹ In another randomised study involving 1,800 patients (COMPARE), EESs were associated with lower rate of definite or probable stent thrombosis at 5 years compared with PESs (3.1% versus 5.9%, $p=0.005$).²⁰

The differences in clinical outcomes were less apparent in randomised trials comparing EESs with SESs than with PESs. In the SORT OUT IV trial, 1,390 patients with coronary artery disease were randomised to either an EES or SES. At 18 months, the rate of definite stent thrombosis was lower with EESs compared with SESs (0.2% versus 0.9%, 95% CI: 0.07–0.88).²¹ In contrast, in a large prospective randomised study, BASKET PROVE, there was no significant difference between the rates of stent thrombosis in SESs and EESs at 2 years.²²

In the EXAMINATION trial, 1,504 patients with ST-segment elevation myocardial infarction were randomised to EESs or BMSs.²³ At 1 year, stent thrombosis rates were significantly lower in the EES group (0.5% versus 1.9% with definite stent thrombosis and 0.9% versus 2.5% with definite or probable stent thrombosis, $p=0.019$).²³ In a meta-analysis of five randomised trials involving a total of 4,896 patients, EESs were associated with a significant reduction in definite stent thrombosis (OR: 0.41, CI: 0.22–0.76, $p=0.005$) and definite or probable stent thrombosis (OR: 0.48, 95% CI: 0.31–0.73, $p<0.001$).²⁴

Zotarolimus-eluting stents

The clinical trials that support the superiority of ZESs are not as robust as those which support the use of EESs. The two FDA-approved ZESs are Endeavor and Resolute. Resolute ZESs use a

BioLinx tripolymer coating instead of the phosphorylcholine polymer used in E-ZES, which extends the elution of zotarolimus to a longer period of time (180 days versus 30 days).²⁵

ENDEAVOR IV is a large randomised trial comparing E-ZES with PESs.²⁶ At 5 years, the overall definite/probable stent thrombosis rates were similar between the two groups (1.3% versus 2%, $p=0.042$).²⁶ However, the rate of very late stent thrombosis was significantly lower with ZESs than with PESs (0.4% versus 1.8%, $p=0.012$).²⁶ Similarly, in a randomised trial conducted in China, there was no difference between the two stents in the rates of definite or probable stent thrombosis, or late stent thrombosis at the end of 1 year.²⁵

The superiority of E-ZES in comparison to C-SES in terms of reducing the rate of stent thrombosis has not yet been established. In the ENDEAVOR III trial, 436 patients were randomised to E-ZES or C-SES.²⁷ At 5 years, though the pre-specified end points of all-cause mortality and myocardial infarction were significantly lower in E-ZES, the rates of stent thrombosis were very low and similar in both groups (0.7% ZESs versus 0.9% SES, $p=1.0$).²⁷ In another randomised study of 1,162 patients, SORT OUT III, the rate of very late stent thrombosis beyond 12 months was similar between E-ZES and C-SES.²⁸ Similar results were observed in a very large randomised trial, PROTECT, involving 8,791 patients.²⁹ At 3 years, the rates of definite or probable stent thrombosis did not differ between E-ZES and C-SES (1.4% E-ZES versus 1.8% for C-SES, $p=0.22$).²⁹ To date, there are no large-scale clinical trials directly comparing Resolute ZESs to C-SES.

In a study combining patient-level data from 6 prospective randomised trials involving 2,132 patients treated with E-ZES and 596 patients treated with a BMSs, no difference in the rate of definite or probable stent thrombosis was observed at 5 years (0.8% versus 1.7%, $p=0.21$).³⁰ There are no trials comparing Resolute ZESs directly with BMSs.

Given the low incidence of stent thrombosis, large sample sizes are required to detect significant differences in rates between stents. Most of the trials noted above were not powered sufficiently for this. Hence, a large network meta-analysis including a total of 49 randomised trials and 50,844 patients was conducted by Palmerini et al.³¹ to investigate if there was a significant difference in stent thrombosis rates. At 1 year, CoCr-EESs were associated with a significantly lower rate of

stent thrombosis compared with BMSs (OR: 0.27, 95% CI: 0.08-0.74), PESs (OR: 0.28, 95% CI: 0.16-0.48), SESs (OR: 0.41, 95% CI: 0.24-0.70), E-ZES (OR: 0.21, 95% CI: 0.10-0.44), and Resolute ZESs (OR: 0.14, 95% CI: 0.03-0.47).³¹ At 2 years, CoCr-EESs were associated with a lower rate of stent thrombosis than BMSs, results that have not been seen with other DESs.³¹ Even at 2 years, the sustained reduction in stent thrombosis incidence in patients with a CoCr-EES compared with BMS has been pivotal in the evolution of PCI, proving the relative safety and efficacy of second-generation DESs compared with BMSs.¹⁸

Optimal Duration of Dual Antiplatelet Therapy for Prevention of Stent Thrombosis in the Era of Second-Generation Drug-Eluting Stents

The optimal duration of DAPT after PCI with second-generation DESs in order to balance the risk of stent thrombosis and bleeding complications

is currently controversial. While 2014 European Guidelines on Myocardial Revascularisation changed the duration of DAPT to 6 months after PCI with second-generation DESs in patients with stable coronary artery disease, the American College of Cardiology/American Heart Association (ACC/AHA) guidelines on PCI recommend 6-12 months of DAPT.^{32,33} The prior recommendation of extending DAPT to ≥ 1 year was based on observational studies with first-generation DESs.^{34,35}

Recently, several randomised trials performed in patients with second-generation DESs showed non-inferiority in a shorter duration DAPT (3 months or 6 months) compared with longer duration DAPT (12 months or 24 months).³⁶⁻⁴¹ Consistently in these trials, the risk of major cardiovascular adverse events and stent thrombosis was not different, while the risk of bleeding increased with longer duration DAPT (Table 1).

Table 1: Randomised trials of second-generation drug-eluting stents (DESs) comparing shorter and longer duration of dual antiplatelet therapy.

Study	Stent	Number of patients in each treatment group (n)	Primary end point	Follow-up duration after randomisation	Results of primary end point	Any significant difference in rates of stent thrombosis?
SECURITY, 2014 ³⁶	Any second-generation DES	6 months (682) 12 months (717)	Cardiac death, MI, CVA, stent thrombosis, bleeding	1 year	Non-inferiority proved	No (0.3 % vs. 0.4%, p=0.694)
ITALIC, 2014 ³⁹	Everolimus-eluting stent	6 months (953) 24 months (941)	Death, MI, CVA, TVR, bleeding	1 year	Non-inferiority proved	No (0 patients in 6 month group vs. 3 in 24 month group)
ISAR-SAFE, 2014 ⁴⁰	Everolimus-eluting stent	6 months (1,997) 12 months (2,003)	Death, MI, CVA, stent thrombosis, bleeding	9 months	Non-inferiority proved	No (0.3 % vs. 0.2 %, p=0.49)
OPTIMIZE, 2013 ³⁸	Zotarolimus-eluting stent	3 months (1,563) 12 months (941)	Death, MI, CVA, major bleeding	1 year	Non-inferiority proved	No (0.3% vs. 0.1%, 95% CI: 0.44-35.49)
RESET, 2012 ³⁷	Endeavor Zotarolimus-eluting stent	3 months (1,059) 12 months (1,058)	Cardiac death, MI, stent thrombosis, TVR, major bleeding	1 year	Non-inferiority proved	No (0.2% vs. 0.3%, p=0.65)
EXCELLENT, 2012 ⁴¹	Everolimus-eluting stent	6 months (722) 12 months (721)	Cardiac death, MI, TVR, stent thrombosis	1 year	Non-inferiority proved	No (0.9% vs. 0.1%, p=0.10)

MI: myocardial infarction; CVA: cerebrovascular accident; TVR: target vessel revascularisation.

However, it is important to note that these trials are not powered adequately to determine a significant difference in the rate of stent thrombosis. Hence, despite the results of these randomly controlled trials (RCTs), the optimal duration remains controversial. In a recent large, multicentre trial, 9,961 patients with DESs (46.7% EES, 26.9% PES, 12.8% ZES, and 11.5% SES) were randomised to 12 or 30 months of DAPT.⁴² While the rates of stent thrombosis and myocardial infarction were significantly reduced as the duration of DAPT increased, the rate of moderate-to-severe bleeding increased.⁴² The rate of death from any cause was higher in the longer DAPT therapy group, despite reduced rates of stent thrombosis and myocardial infarction (2.0% versus 1.5%, $p=0.05$).⁴² Similar results were noted in a meta-analysis of 11 RCTs involving 31,666 patients.⁴³ Though longer DAPT (≥ 1 year) reduces the risk of myocardial infarction and stent thrombosis, it is associated with increased risk of bleeding complications and mortality from non-cardiovascular causes.⁴³ In patients with stable coronary artery disease, a shorter DAPT duration of 3–6 months is recommended, especially if the patient is at high risk of bleeding and has a second-generation DESs. After PCI for acute coronary syndrome, DAPT for a duration of 1 year is recommended regardless of the type of stent.

Consideration of the optimal duration of DAPT after PCI is further complicated by recent increases in the use of new P2Y₁₂ inhibitors (prasugrel and ticagrelor). Compared with clopidogrel, these newer agents demonstrate a more potent suppression of platelet activity and are associated with significantly reduced rates of stent thrombosis and increased rates of bleeding complications.^{44,45} Studies of the optimal duration of DAPT with these newer agents are limited. The current guidelines do not differentiate the duration of DAPT based on the antiplatelet agent used.^{32,33} In a recent large-scale multicentre trial involving 21,162 patients who presented with myocardial infarction >1 year previously, patients were randomised to ticagrelor 90 mg or 60 mg twice daily for a median duration of 33 months or placebo; results demonstrated an association between ticagrelor and a significant reduction in the risk of cardiovascular death, myocardial infarction, or stroke, and an increased risk of bleeding, when compared with placebo.⁴⁶ Given the increased risk of bleeding complications and mortality from non-cardiovascular cause, DAPT therapy for ≥ 1 year should be individualised based on clinical and anatomical risk factors.

Future Directions

The success of biocompatible fluorocopolymers in reducing the rate of stent thrombosis has facilitated the next-generation DESs with either biodegradable polymers (third-generation DESs) or bioresorbable vascular scaffolds (BVS; considered fourth-generation DESs).

Third-generation drug-eluting stents

Third-generation stents consist of a metallic stent platform, with the drug being delivered from an ultra-thin bioabsorbable polymer applied to the outer stent surface. Once the drug is eluted, the polymer is completely reabsorbed, leaving behind the endothelialised BMSs struts. Though designed to reduce the risk of stent thrombosis, such a reduction has not yet been demonstrated in randomised trials. In a recent trial comparing the Synergy™ stent (a platinum chromium metal alloy with bioabsorbable poly[D,L-lactide-co-glycolide] abluminal everolimus-eluting polymer) with EES, the rate of definite stent thrombosis was similar after 12 months (2.6% versus 1.7%, $p=0.21$).⁴⁷ Future randomised studies are needed to evaluate long-term outcomes regarding late stent thrombosis with these stents.

Bioresorbable vascular scaffolds

BVSs are made of lactic acid or magnesium-based polymers. These stents are designed to restore normal vasomotor tone and increase the lumen calibre through positive remodelling following degradation of the stent. Theoretically, the risk of late stent thrombosis should be reduced as no metallic stent struts remain exposed to the blood stream after stent degradation. The initial data from large registry studies showed significant increases in the rate of device-related early or sub-acute stent thrombosis with BVSs compared with metallic stents.^{48–50} However, in the recent randomised ABSORB III trial, where everolimus-eluting BVSs (Absorb BVS) were compared with CoCr-EESs in 2,008 patients, there was no significant difference in the rate of stent thrombosis at 12 months (1.5% versus 0.7%, $p=0.13$).⁵¹ In a recent patient-level pooled meta-analysis of four randomised trials, there was a non-significant increase in the rate of stent thrombosis with BVS.⁵² Though shown to be non-inferior when compared with second-generation DESs in terms of major cardiovascular events at 1 year in the ABSORB III trial⁵¹ and in the recent meta-analysis,⁵² the deliverability and radial strength of these stents may be factors which

limit their widespread usage. Future stent designs should aim at reducing strut thickness while maintaining radial and longitudinal strength to improve deliverability of BVS. Currently, the optimal duration of DAPT for BVS or stents with biodegradable polymers is unknown. Future large-scale randomised trials are needed to address these issues.

CONCLUSION

Stent thrombosis is an uncommon but life-threatening complication of PCI. Late and very late stent thrombosis was a major concern with first-generation DESs. With the improved features of the second-generation DESs (thinner stent

struts, biocompatible fluorocopolymers, and use of different anti-proliferative agents) the rate of stent thrombosis has dramatically decreased. Currently, CoCr-EESs have produced the lowest rate of stent thrombosis within 2 years of placement of all available stents including BMSs. Though the optimal duration of DAPT in patients with second-generation DESs is still controversial, 6-month therapy might result in reduced bleeding complications without increasing the occurrence of major cardiovascular events. The next-generation DESs include stents with biodegradable polymers and bioresorbable scaffolds. However, large-scale randomised trials are needed to definitively evaluate the efficacy and safety of these third and fourth-generation stents in the future.

REFERENCES

1. Ludman P et al. National Audit of Percutaneous Coronary Interventions. Annual Public Report. January 2013 - December 2013. Available at: http://www.ucl.ac.uk/nicor/audits/adultpercutaneous/documents/2013_annual_report_pdf. Last accessed: 24 November 2015.
2. Cutlip DE et al. Clinical restenosis after coronary stenting: perspectives from multicenter clinical trials. *J Am Coll Cardiol.* 2002;40(12):2082-9.
3. Camenzind E et al. Stent thrombosis late after implantation of first-generation drug-eluting stents: a cause for concern. *Circulation.* 2007;115(11):1440-55.
4. Wenaweser P et al. Incidence and correlates of drug-eluting stent thrombosis in routine clinical practice. 4-year results from a large 2-institutional cohort study. *J Am Coll Cardiol.* 2008; 52(14):1134-40.
5. Burzotta F et al. Angiographic and clinical outcome of invasively managed patients with thrombosed coronary bare metal or drug-eluting stents: the OPTIMIST study. *Eur Heart J.* 2008;29(24):3011-21.
6. Cutlip DE et al.; Academic Research Consortium. Clinical end points in coronary stent trials: a case for standardized definitions. *Circulation.* 2007;115(17):2344-517.
7. Finn AV et al. Vascular responses to drug eluting stents: importance of delayed healing. *Arterioscler Thromb Vasc Biol.* 2007;27(7):1500-10.
8. Finn AV et al. Pathological correlates of late drug-eluting stent thrombosis strut coverage as a marker of endothelialization. *Circulation.* 2007;115(18):2435-41.
9. Nakazawa G et al. Coronary responses and differential mechanisms of late stent thrombosis attributed to first-generation sirolimus- and paclitaxel-eluting stents. *J Am Coll Cardiol.* 2011;57(4):390-8.
10. Tada T et al. Impact of stent strut thickness on arterial healing after drug-eluting stents implantation assessed by optical coherence tomography. *Eur Heart J.* 2013;34(Suppl 1):3935.
11. Kolandaivelu K et al. Stent thrombogenicity early in high-risk interventional settings is driven by stent design and deployment and protected by polymer-drug coatings. *Circulation.* 2011;123(13):1400-9.
12. Virmani R et al. Localized hypersensitivity and late coronary thrombosis secondary to a sirolimus-eluting stent: should we be cautious? *Circulation.* 2004;109(6):701-5.
13. Nebeker JR et al. Hypersensitivity cases associated with drug-eluting coronary stents: a review of available cases from the Research on Adverse Drug Events and Reports (RADAR) project. *J Am Coll Cardiol.* 2006;47(1):175-81.
14. Otsuka F et al. Pathology of second-generation everolimus-eluting stents versus first-generation sirolimus- and paclitaxel-eluting stents in humans. *Circulation.* 2014;129(2):211-23.
15. Hezi-Yamit A et al. Impact of polymer hydrophilicity on biocompatibility: implication for DES polymer design. *J Biomed Mater Res A.* 2009;90(1):133-41.
16. Price MJ, Mosley WJ. "Fundamentals of Drug-Eluting Stent Design," Matthew J Price (ed.), *Coronary Stenting: A Companion to Topol's Textbook of Interventional Cardiology* (2012), Philadelphia: Elsevier Saunders, pp.13-27.
17. Kukreja N et al. Xience V everolimus-eluting coronary stent. *Expert Rev Med Devices.* 2009;6(3):219-29.
18. Palmerini T et al. Stent thrombosis with drug-eluting stents: is the paradigm shifting? *J Am Coll Cardiol.* 2013;62(21):1915-21.
19. Dangas GD et al. Meta-analysis of everolimus-eluting versus paclitaxel-eluting stents in coronary artery disease: final 3-year results of the SPIRIT clinical trials program (Clinical Evaluation of the Xience V Everolimus Eluting Coronary Stent System in the Treatment of Patients with De Novo Native Coronary Artery Lesions). *JACC Cardiovasc Interv.* 2013;6(9):914-22.
20. Smits PC et al. Final 5-Year Follow-Up of a Randomized Controlled Trial of Everolimus- and Paclitaxel-Eluting Stents for Coronary Revascularization in Daily Practice: The COMPARE Trial (A Trial of Everolimus-Eluting Stents and Paclitaxel Stents for Coronary Revascularization in Daily Practice). *JACC Cardiovasc Interv.* 2015;8(9):1157-65.
21. Jensen LO et al.; Scandinavian Organization for Randomized Trials with Clinical Outcome IV (SORT OUT IV) Investigators. Randomized comparison of everolimus-eluting and sirolimus-eluting stents in patients treated with percutaneous coronary intervention: the Scandinavian Organization for Randomized Trials with Clinical Outcome IV (SORT OUT IV). *Circulation.* 2012;125(10):1246-55.
22. Kaiser C et al.; BASKET-PROVE Study Group. Drug-eluting versus bare-metal stents in large coronary arteries. *N Engl J Med.* 2010;363(24):2310-9.
23. Sabate M et al. Everolimus-eluting stent versus bare-metal stent in ST-segment elevation myocardial infarction

- (EXAMINATION): 1 year results of a randomised controlled trial. *Lancet*. 2012; 380(9852):1482-90.
24. Valgimigli M et al. Effects of cobalt-chromium everolimus eluting stents or bare metal stent on fatal and non-fatal cardiovascular events: patient level meta-analysis. *BMJ*. 2014;349:g6427.
25. Gujja K et al. "Efficacy and safety of bare metal and drug eluting stents." Matthew Price (ed.), *Coronary stenting: a companion to Topol's Textbook of interventional cardiology* (2012), Philadelphia: Elsevier Saunders, pp.81-92.
26. Kirtane AJ et al.; ENDEAVOR IV Investigators. The "final" 5-year follow-up from the ENDEAVOR IV trial comparing a zotarolimus-eluting stent with a paclitaxel-eluting stent. The "final" 5-year follow-up from the ENDEAVOR IV trial comparing a zotarolimus-eluting stent with a paclitaxel-eluting stent. *JACC Cardiovasc Interv*. 2013;6(4):325-33.
27. Kandzari DE et al. Late-term clinical outcomes with zotarolimus- and sirolimus-eluting stents. 5-year follow-up of the ENDEAVOR III (A Randomized Controlled Trial of the Medtronic Endeavor Drug [ABT-578] Eluting Coronary Stent System Versus the Cypher Sirolimus-Eluting Coronary Stent System in De Novo Native Coronary Artery Lesions). *JACC Cardiovasc Interv*. 2011;4(5):543-50.
28. Rasmussen K et al.; SORT OUT III study group. Efficacy and safety of zotarolimus-eluting and sirolimus-eluting coronary stents in routine clinical care (SORT OUT III): a randomised controlled superiority trial. *Lancet*. 2010;375(9720):1090-9.
29. Camenzind E et al.; PROTECT Steering Committee and Investigators. Stent thrombosis and major clinical events at 3 years after zotarolimus-eluting or sirolimus-eluting coronary stent implantation: a randomised, multicenter, open-label, controlled trial. *Lancet*. 2012; 380(9851):1396-405.
30. Eisenstein EL et al. Long-term clinical and economic analysis of the Endeavor drug-eluting stent versus the Driver bare-metal stent: 4-year results from the ENDEAVOR II trial (Randomized Controlled Trial to Evaluate the Safety and Efficacy of the Medtronic AVE ABT-578 Eluting Driver Coronary Stent in De Novo Native Coronary Artery Lesions). *JACC Cardiovasc Interv*. 2009;2(12): 1178-87.
31. Palmerini T et al. Stent thrombosis with drug-eluting and bare-metal stents: evidence from a comprehensive network meta-analysis. *Lancet*. 2012; 379(9824):1393-402.
32. Windecker S et al. 2014 ESC/EACTS guidelines on myocardial revascularization. *Rev Esp Cardiol*. 2015;68(2):144.
33. Levine GN et al; American College of Cardiology Foundation; American Heart Association Task Force on Practice Guidelines; Society for Cardiovascular Angiography and Interventions. 2011 ACCF/AHA/SCAI guideline for percutaneous coronary intervention: a report of the American College of Cardiology Foundation/American Heart Association Task Force on Practice Guidelines and the Society for Cardiovascular Angiography and Interventions. *Catheter Cardiovasc Interv*. 2013;82(4):E266-355.
34. Bavry AA et al. Late thrombosis of drug-eluting stents: a meta-analysis of randomized clinical trials. *Am J Med*. 2006;119(12):1056-61.
35. Daemen J et al. Early and late coronary stent thrombosis of sirolimus-eluting and paclitaxel-eluting stents in routine clinical practice: data from a large two-institutional cohort study. *Lancet*. 2007;369(9562):667-78.
36. Colombo A et al. Second-generation drug-eluting stent implantation followed by 6- versus 12-month dual antiplatelet therapy: the SECURITY randomized clinical trial. *J Am Coll Cardiol*. 2014; 64(20):2086-97.
37. Kim BK et al; RESET Investigators. A new strategy for discontinuation of dual antiplatelet therapy: the RESET Trial (REal Safety and Efficacy of 3-month dual antiplatelet Therapy following Endeavor zotarolimus-eluting stent implantation). *J Am Coll Cardiol*. 2012;60(15):1340-8.
38. Feres F et al; OPTIMIZE Trial Investigators. Three vs twelve months of dual antiplatelet therapy after zotarolimus-eluting stents: the OPTIMIZE randomized trial. *JAMA*. 2013;310(23):2510-22.
39. Gilard M et al. 6- versus 24-month dual antiplatelet therapy after implantation of drug-eluting stents in patients nonresistant to aspirin: the randomized, multicenter ITALIC trial. *J Am Coll Cardiol*. 2015;65(8):777-86.
40. Schulz-Schüpke S et al. Intracoronary Stenting and Antithrombotic Regimen: Safety And Efficacy of 6 Months Dual Antiplatelet Therapy After Drug-Eluting Stenting (ISAR-SAFE) Trial Investigators. ISAR-SAFE: a randomized, double-blind, placebo-controlled trial of 6 vs. 12 months of clopidogrel therapy after drug-eluting stenting. *Eur Heart J*. 2015;36(20): 1252-63.
41. Gwon HC et al. Six-month versus 12-month dual antiplatelet therapy after implantation of drug-eluting stents: the Efficacy of Xience/Promus Versus Cypher to Reduce Late Loss After Stenting (EXCELLENT) randomized, multicenter study. *Circulation*. 2012;125(3):505-13.
42. Mauri L et al.; DAPT Study Investigators. Twelve or 30 months of dual antiplatelet therapy after drug-eluting stents. *N Engl J Med*. 2014;371(23):2155-66.
43. Palmerini T et al. Mortality in patients treated with extended duration dual antiplatelet therapy after drug-eluting stent implantation: a pairwise and Bayesian network meta-analysis of randomised trials. *Lancet*. 2015;385(9985):2371-82.
44. Wallentin L et al. Ticagrelor versus clopidogrel in patients with acute coronary syndromes. *N Engl J Med*. 2009; 361(11):1045-57.
45. Wiviott SD et al. Prasugrel versus clopidogrel in patients with acute coronary syndromes. *N Engl J Med*. 2007; 357(20):2001-15.
46. Bonaca MP et al. Long-term use of ticagrelor in patients with prior myocardial infarction. *N Engl J Med*. 2015;372(19):1791-800.
47. Kereiakes DJ et al. Efficacy and safety of a novel bioabsorbable polymer-coated, everolimus-eluting coronary stent: the EVOLVE II Randomized Trial. *Circ Cardiovasc Interv*. 2015;8(4). doi: 10.1161/CIRCINTERVENTIONS.114.002372.
48. Capodanno D et al. Percutaneous coronary intervention with everolimus-eluting bioresorbable vascular scaffolds in routine clinical practice: early and midterm outcomes from the European multicentre GHOST-EU registry. *EuroIntervention*. 2015;10:1144-53.
49. Kraak RP et al. Initial experience and clinical evaluation of the Absorb bioresorbable vascular scaffold (BVS) in real-world practice: the AMC Single Centre Real World PCI Registry. *EuroIntervention*. 2015;10(10):1160-8.
50. Jaguszewski M et al. Feasibility of second-generation bioresorbable vascular scaffold implantation in complex anatomical and clinical scenarios. *Clin Res Cardiol*. 2015;104(2):124-35.
51. Ellis SG et al; ABSORB III Investigators. Everolimus-Eluting Bioresorbable Scaffolds for Coronary Artery Disease. *N Engl J Med*. 2015;373(20):1905-15.
52. Stone GW et al. 1-year outcomes with the Absorb bioresorbable scaffold in patients with coronary artery disease: a patient-level, pooled meta-analysis. *Lancet*. 2016. doi: 10.1016/S0140-6736(15)01039-9. [Epub ahead of print].
53. Ormiston JA et al. Stent Longitudinal Integrity. Bench Insights into a clinical problem. *JACC Cardiovasc Interv*. 2011; 4:1310-7.