

# RETROGRADE INTRARENAL SURGERY FOR COMPLEX STONES IN A TODDLER WITH CONGENITAL RENAL ANOMALIES: TECHNICAL DETAILS

Murat Can Kiremit, \*Selcuk Guven, Rahim Horuz, Bulent Erkurt, Selami Albayrak

*Department of Urology, Medical Faculty of Medipol University, Istanbul, Turkey*

*\*Correspondence to selcukguven@hotmail.com*

**Disclosure:** The authors have declared no conflicts of interest.

**Received:** 25.11.14 **Accepted:** 20.02.15

**Citation:** EMJ Nephrol. 2015;3[1]:70-74.

---

## ABSTRACT

We report herein the management of a challenging case due to anatomic and stone-related complications in a 37-month-old Caucasian toddler with megacalycosis and complex stone in the left kidney and duplicated ureter on the right side.

**Keywords:** Retrograde intrarenal surgery, flexible ureteroscopy, micropercutaneous nephrolithotomy (microperc), percutaneous nephrolithotomy, kidney, complex stone.

---

## INTRODUCTION

Since a surgeon's first experience with many complex endourological techniques is generally in adults and then later implemented in children, knowledge and expertise in paediatric complex renal stone treatment falls behind that for adults. Percutaneous nephrolithotomy (PCNL) is considered as the first-line treatment option in complex renal stones, either alone or in combination with shock wave lithotripsy (SWL).<sup>1</sup> Departments specialised in endourological stone treatment are able to employ the most up-to-date treatment modalities in paediatric stone cases. In addition to PCNL, retrograde intrarenal surgery (RIRS) and micropercutaneous nephrolithotomy (microperc) may also be used for the treatment of complex renal stones.<sup>2</sup> Limited data are available regarding percutaneous treatment and/or retrograde intrarenal management of kidney stones in children with congenital anomalies. We report herein the management of a challenging case due to anatomic and stone-related complications in a 37-month-old Caucasian toddler with megacalycosis and complex stone in the left kidney and duplicated ureter on the right side.

## CASE

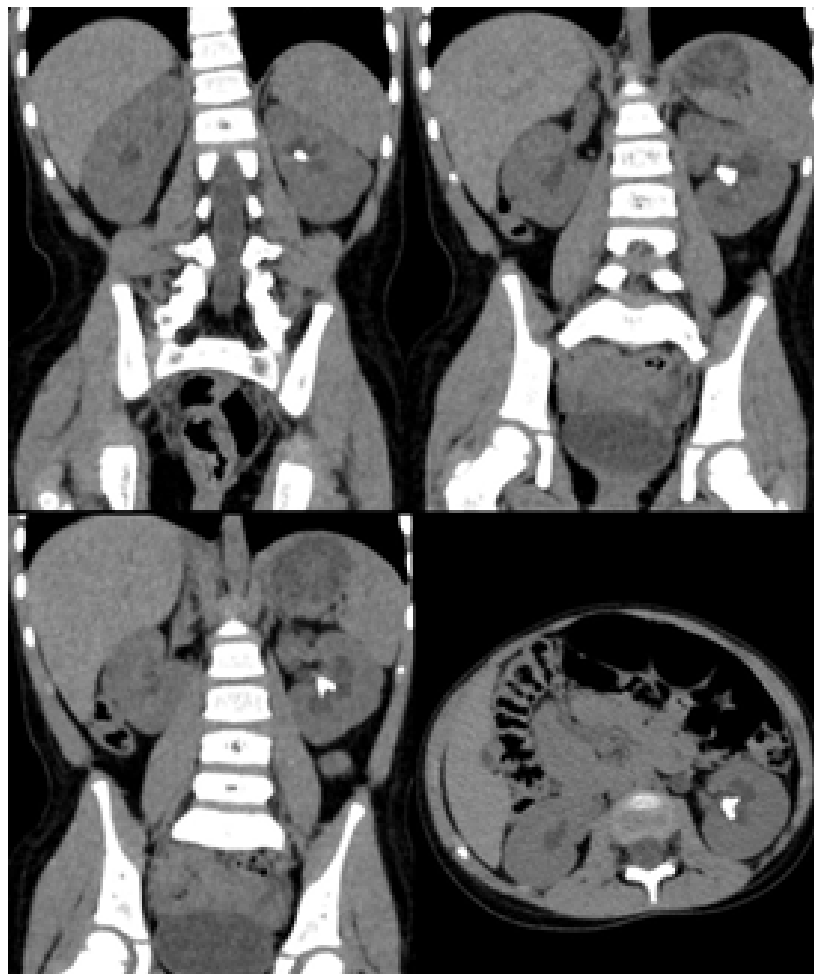A 37-month-old Caucasian female was referred to our department with left kidney stone and recurrent urinary tract infection complaints over the previous 2 years. The patient had been diagnosed with left renal stone in an outpatient clinic 2 years before. She had an 8 mm renal stone in the left lower pole, and 2 mm and 3 mm renal stones in the middle pole. As the renal stones were observed to have grown at follow-up she was referred to our centre. Her examination revealed several stones filling two calyces in the left lower pole (with the largest being 35 mm in diameter), one in the middle pole filling one calyx and extending towards the pelvis, and several in the upper pole calyces (Figure 1). A duplicated collecting system on the right and rotation anomalies on the left were also diagnosed (Figure 2). There was no growth in the urine culture and blood values were within normal limits. The patient's weight and height were 13 kg and 85 cm, respectively. Removal of the renal stones using endoscopic techniques was decided. Despite the greater experience available with PCNL, RIRS was considered due to the presence of stones in many calyces and concern that a stone-free status could not be achieved with monotherapy and

limited fluoroscopy time. Regardless of the technique employed, it was decided that SWL would be applied for any residual stones. The patient's family was informed about the relevant treatment options and related risks. RIRS was considered as the first-line treatment modality to access the renal stones. If the ureteral access sheath (UAS) could not be placed due to the ureteral anatomy, the surgical team was also prepared for percutaneous intervention.

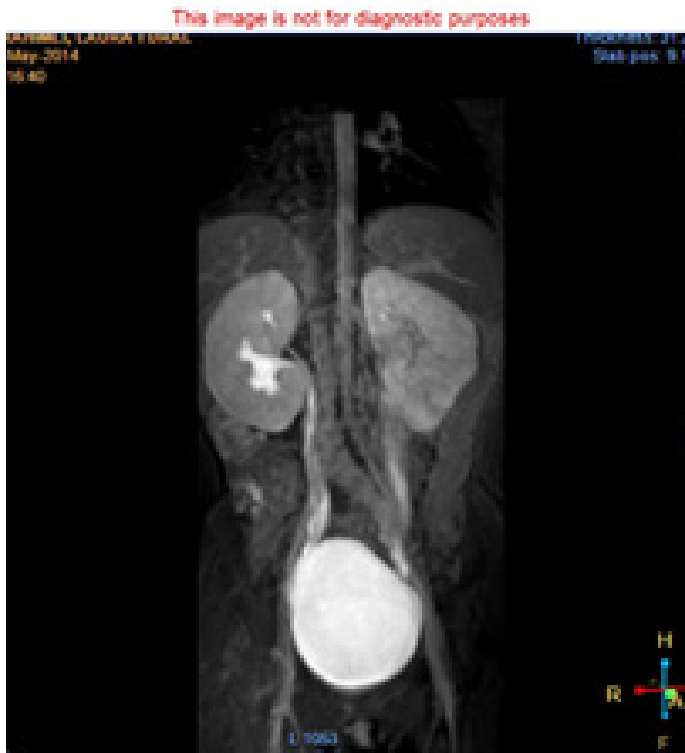## OPERATION THEATRE

The patient underwent RIRS under general anaesthesia in the standard lithotomy position. Two lead collars were used in the present case, as these were considered to be better shaped for positioning during cystogram and intervention to the kidney stones. The cystogram obtained prior to RIRS was unremarkable. Cystoscopic evaluation was performed by 7.5 Fr paediatric semi-rigid ureteroscope (STORZ, Tuttlingen, Germany), and

two ureter orifices were observed on the right and one on the left. A hybrid guide wire was introduced from the left ureteral orifice and advanced until the upper calyx. Another guidewire used as a safety guidewire and a 9.5 Fr 28 cm UAS were also placed in the proximal ureter over the first guidewire under fluoroscopy. The retrograde pyelogram revealed high-insertion ureteropelvic junction (UPJ), narrow infundibulopelvic angle, megacalycosis, and a small renal pelvis (Figure 3). Access of the flexible ureteroscope (Flex-X2, STORZ, Tuttlingen, Germany) to the stone was difficult due to the small pelvis and high insertion of the UPJ. The pelvic stone could be partially fragmented by holmium: YAG laser, whereas calyceal stones in the lower and middle poles were fragmented with either 272-micron (0.6 J and 10 Hz) or 200-micron (0.6 J and 8 Hz) laser probes (Sphinx, LISA, Katlenburg-Lindau, Germany). All the stones were fragmented until they were considered small enough to pass spontaneously.



**Figure 1:** Stones filling two calyces in the left lower pole, one in the middle pole filling one calyx and extending towards the pelvis, and several in the upper pole calyces.



**Figure 2: A duplicated collecting system on the right and rotation anomalies on the left.**

A manual irrigation pump was used during the procedure. Sufficient samples for stone analysis were taken by using a basket catheter. After the placement of a 16 cm double J catheter and a 10 Fr Foley catheter the intervention was completed with a total fluoroscopy time (including diagnostic imaging) of 70 seconds. The postoperative follow-up was uneventful. The patient was discharged on the third postoperative day. As the patient was from abroad, she was hospitalised for an additional day.

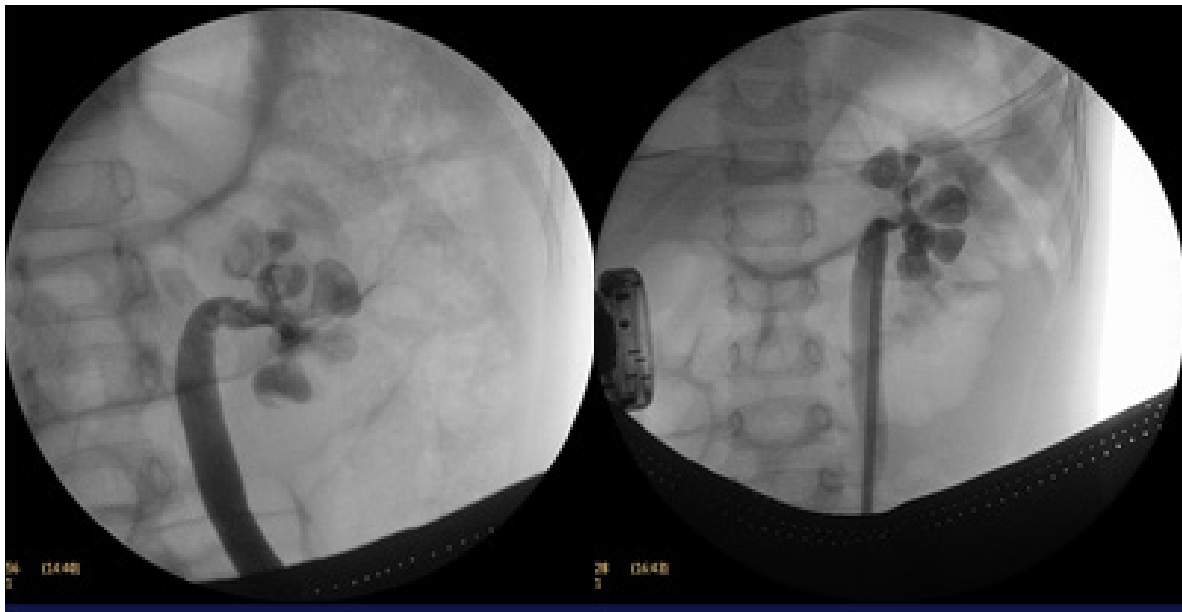
## DISCUSSION

Although SWL is a good option in children with renal stones up to 20 mm in diameter, miniperc is considered the best choice for stones larger than 20 mm.<sup>1,3,4</sup> On the other hand, RIRS is an effective and well-tolerated option that can be used to manage renal stones in toddlers.<sup>5</sup> In the present case, the stones were settled in different calyces and thus RIRS alone or combined with miniperc or microperc was preferred over direct miniperc.<sup>6</sup> In paediatric renal stone cases, contrast-enhanced computed tomography (CT) or intravenous urogram imaging are not considered in the routine initial radiologic evaluation due to the inherent side-effects.<sup>7</sup> In line with the paediatric protocol, urinary CT without contrast material

was utilised. Consequently, duplicated ureter on the right kidney and megacalycosis in the left kidney were seen in the retrograde pyelography performed during the intervention. Both megacalycosis and duplex collecting systems are congenital anomalies. The latter is seen in 0.7% of the normal adult population and in 2-4% of patients investigated for urinary tract symptoms. Similarly, megacalycosis is also a rare congenital developmental anomaly of the kidney characterised by nonobstructive dilatation of the renal calyces with symptoms such as urinary tract infection and stone formation due to stagnant urine. As there was no vesicoureteral reflux or hydronephrosis, the present anomalies were decided to be followed after stone management.

UAS usage differs according to the preference of the surgeon: there are reports of UAS usage in all patients<sup>8-10</sup> as well as in none.<sup>11</sup> In our centre, we prefer to use UAS in all patients. In paediatric cases, we use 13, 20, or 28 cm 9.5 Fr UAS depending on the length of ureter. However, we prefer to avoid using UAS in boys to prevent urethral stricture. In some cases, ureteral balloon dilatation is required. In the present case, although the UAS could not be placed in the ureter on the first attempt, it was placed easily after passage of the internal sheath with slight dilatation. On the other hand, due to the left kidney anomaly and UPJ anatomy, the technical use of the flexible ureteroscope was difficult. Multiple calyceal stones and narrow infundibulopelvic angle made access to the lower pole difficult. Use of a 200-micron laser probe for access to the lower pole facilitated the procedure. Percutaneous access was not necessary since RIRS was feasible despite the difficulties. According to the post-ureteroscopic lesion scale,<sup>12</sup> damage to the ureter after the intervention was Grade 1.

One of our main concerns in complex renal stone treatment in children is sepsis. Minimising the laser stone fragmentation time and maintaining low intrapelvic and intrarenal pressure take on greater importance in the growing toddler's kidney. UAS usage is known to lower intrapelvic pressure up to 57-75%.<sup>13</sup> Moreover, using UAS may help in removing the stone fragments more easily. The stone fragmentation time was minimised to the greatest extent possible. Fragmentation was preferred over dusting. The manual irrigation pump was only used during the procedure if absolutely necessary.



**Figure 3: The retrograde pyelogram revealed high-insertion ureteropelvic junction, narrow infundibulopelvic angle, megacalycosis, and a smaller pelvis.**

In paediatric PCNL, miniperc, RIRS, and microperc are the treatment modalities that can yield high stone-free rates with monotherapy compared with SWL. Our approaches to adult kidney stones have changed with technological developments and increase in expertise. Our experiences in adults enable us to transfer these developments to children. With the changing paradigms in paediatric renal stones, reports of application of RIRS in children have begun to accumulate in the literature. However, RIRS series in paediatric renal stones include school-aged children up to 17 years of age, and ureteral stones. Detailed reports about toddlers and preschool children are

limited. Moreover, approaches to paediatric renal stones in the presence of congenital anomalies are of particular importance, and our knowledge about the use of RIRS in these patients is limited.

In this case study, we provide details about a challenging case with complex stones and congenital anomalies in an era of multiple endourological intervention alternatives by reviewing the technical details of RIRS. RIRS was applied in this patient. In Turkey, where stone disease is endemic, urologists should gain expertise in all endourological treatment modalities for recurrent stone disease, especially for use in high-risk patients.

## REFERENCES

1. Türk C et al. Guidelines on Urolithiasis. European Association of Urology. 2014.
2. Rioja J et al. A plea for centralized care for ureteroscopy: results from a comparative study under different conditions within the same center. *J Endourol.* 2011;25(3):425-9.
3. Guven S et al. Percutaneous nephrolithotomy in children in different age groups: data from the Clinical Research Office of the Endourological Society (CROES) Percutaneous Nephrolithotomy Global Study. *BJU Int.* 2013;111(1):148-56.
4. Guven S et al. Successful percutaneous nephrolithotomy in children: multicenter study on current status of its use, efficacy and complications using Clavien classification. *J Urol.* 2011;185(4):1419-24.
5. Erkurt B et al. Treatment of renal stones with flexible ureteroscopy in preschool age children. *Urolithiasis.* 2014;42(3):241-5.
6. Hoznek A et al. Modified supine percutaneous nephrolithotomy for large kidney and ureteral stones: technique and results. *Eur Urol.* 2012;61(1):164-70.
7. Brenner DJ, Hall EJ. Computed tomography-an increasing source of radiation exposure. *N Engl J Med.* 2007;357(22):2277-84.
8. Al-Qahtani SM et al. Which ureteral access sheath is compatible with your flexible ureteroscope? *J Endourol.* 2014;28(3):286-90.
9. de la Rosette J et al. The clinical research office of the endourological society ureteroscopy global study: indications, complications, and outcomes in 11,885 patients. *J Endourol.* 2014;28(2):131-9.
10. Unsal A, Resorlu B. Retrograde intrarenal surgery in infants and preschool-age children. *J Pediatr Surg.* 2011;46(11):2195-9.
11. Mokhless IA et al. Retrograde intrarenal

surgery monotherapy versus shock wave lithotripsy for stones 10 to 20 mm in preschool children: a prospective, randomized study. *J Urol.* 2014;191(5 Suppl):1496-9.

12. Schoenthaler M et al. Postureteroscopic lesion scale: a new management modified organ injury scale--evaluation in 435 ureteroscopic patients. *J Endourol.* 2012;26(11):1425-30.

13. Auge BK et al. Ureteral access sheath provides protection against elevated renal pressures during routine flexible ureteroscopic stone manipulation. *J Endourol.* 2004;18(1):33-6.

If you would like Reprints of any article, contact: 01245 334450.