

# Spotlight on Acne

This symposium took place on 13<sup>th</sup> June 2019, as part of the World Congress of Dermatology (WCD) symposium in Milan, Italy

**Chairpeople:** Jerry Tan<sup>1</sup>

**Speakers:** Gabriella Fabbrocini,<sup>2</sup> Linda Stein Gold,<sup>3</sup> Jerry Tan<sup>1</sup>

1. University of Western Ontario and Windsor Clinical Research Inc., Windsor, Ontario, Canada
2. University of Naples Federico II, Naples, Italy
3. Henry Ford Health System, Detroit, Michigan, USA

**Disclosure:** Prof Tan is an advisor, consultant, investigator, and/or speaker for: Almirall, Bausch Health, Boots Walgreens, Botanix, Galderma, Novan, Novartis, and Sun. Prof Fabbrocini reports financial support from Abbvie SRL, Aristeia Education SRL, Beiersdorf SpA, BioDue SpA, Boehringer Ingelheim Italia SpA, Consorzio Formazione Medica SRL, Costanzafarma SRL, Coswell SpA, Crinos SpA, Delife Pharma SRL, Dermaroller GmbH, Devital Service SpA, Dialecticon SRL, Difa Cooper SpA, Editamed SRL, Edizioni Minerva Medica SpA, EMF SRL, Eurestist Network Genie, Galderma Italia SpA, Galderma International SAS, General Topics SRL, Giuliani SpA, Giunti Editore SpA, Hippocratica Imaging SRL, IBSA Farmaceutici Italia SpA, Iromed Group SRL, Istituto Ganassini SpA, L'Oréal Italia SpA, Laboratoires Dermatologiques D'Uriage, Look Around SRL, Meda Pharma SpA, Medi K SRL, Medskin Solutions Dr Suwelack, Meetings & Words SRL, Micom SRL, Momento Medico SRL, New Congress SRL, Pacini Editore SpA, Pierre Fabre Dermo-Cosmetique, Pierre Fabre Italia SpA, Regia Congressi SRL, Sidemast, Sidera SRL, Sintesi Infomedica SRL, Tecniche Nuove Spa, Triumph Comunicazione e Congressi SRL, Università Degli Studi Federico II Facoltà Medicina e Chirurgia, Up Value SRL, Valetudo SRL, Visufarma SpA, and XS Events SRL. Dr Stein Gold reports financial support from: Galderma, Foamix, Sol-Gel, Ortho-Dermatologics, Almirall, Aclaris, and Novartis.

**Acknowledgements:** Writing assistance was provided by Jenny Lloyd (Compass Medical Communications Ltd.).

**Support:** The publication of this article was funded by Galderma. The views and opinions expressed are those of the presenters. Content was reviewed by Galderma for medical accuracy.

**Citation:** EMJ Dermatol. 2019;7[Suppl 6]:2-11.

## Meeting Summary

Prof Fabbrocini gave an overview of the current European and American guidelines for acne treatment. She highlighted some important new recommendations from the Global Alliance consensus, including that oral isotretinoin should be continued until full acne clearance and that early, effective treatment is important to minimise scarring. She then discussed various gaps between guidelines and clinical practice, including adherence, scar prevention, physical modalities, dermocosmetics, skin of colour, diet, and truncal acne. Dr Stein Gold then spoke about the epidemiology of acne and the traditional and emerging concepts relating to its pathogenesis. She discussed the important role of inflammation, which is now known to be present throughout acne progression, and highlighted that inflammation is not just a response to *Cutibacterium acnes* proliferation. She then discussed

the impact of the inflammatory process on the risk of acne scarring, the negative effects of scarring on patients, and the importance of early treatment to minimise or even prevent scarring; the problem of post-inflammatory hyperpigmentation (PIH) in patients with skin of colour; and adult acne, which predominantly affects women. Lastly, she highlighted the under-recognised problem of truncal acne which, despite affecting approximately 50–60% of patients with facial acne, lacks specific treatment guidelines. Prof Tan then discussed some interesting studies on the current and emerging treatments for PIH (tretinoin 0.1% cream, azelaic acid 15.0% gel, dapsone 7.5% gel), adult female acne (dapsone 5.0% gel, azelaic acid 15.0% gel, adapalene 0.1% gel, spironolactone), acne scarring (adapalene 0.3% gel, adapalene 0.1% or 0.3% plus benzoyl peroxide [BPO] 2.5% gel), and truncal acne (dapsone 7.5% gel, azelaic acid 15.0% foam, drospirenone 3 mg/ethinyl oestradiol 0.02 mg, trifarotene 50 µg/g cream). Trifarotene is one of the first treatments that has been shown to be effective and safe for the treatment of truncal acne in a robust Phase III programme.

---

## Current Standard of Care for Acne Patients

Professor Gabriella Fabbrocini

### European Guidelines

For comedonal acne, there is a paucity of direct evidence for its treatment; regardless, there is more evidence for efficacy and tolerability of adapalene over tretinoin/isotretinoin.<sup>1</sup> The European guidelines do not recommend the use of topical antibiotics for comedonal acne, due to the risk of antibiotic resistance. They also do not recommend hormonal anti-androgens, systemic antibiotics, systemic isotretinoin, or artificial ultraviolet (UV) radiation.<sup>1</sup>

For mild-moderate papulopustular acne, combinations of BPO + adapalene or BPO + clindamycin are strongly recommended.<sup>1</sup> Again, there is more evidence for the efficacy and tolerability of adapalene over tretinoin/isotretinoin.<sup>1</sup> Topical antibiotics as monotherapy are not recommended, nor are artificial UV radiation, fixed-dose combination of erythromycin + zinc, or systemic therapy with anti-androgens, antibiotics, and/or isotretinoin.<sup>1</sup>

For severe papulopustular/moderate nodular acne and severe nodular/conglobate acne, isotretinoin is highly recommended.<sup>1</sup> Systemic antibiotic + adapalene + BPO or systemic antibiotic + azelaic acid can also be used, with a further option of systemic antibiotic + adapalene for severe papulopustular/moderate nodular acne. Topical monotherapy is not recommended, nor are oral antibiotic monotherapy, oral anti-androgens, visible light monotherapy, or artificial UV radiation.<sup>1</sup>

### American Guidelines

The American guidelines<sup>2</sup> have simpler definitions of acne (only mild, moderate, or severe) than the European guidelines.<sup>1</sup>

For mild acne, first-line treatments include BPO, topical retinoid, or topical combination therapies (BPO + antibiotic and/or retinoid).<sup>2</sup> Alternatives are to add a topical retinoid or BPO, an alternative retinoid, or topical dapsone.<sup>2</sup>

For moderate acne, first-line treatments are topical combination therapy (BPO + antibiotic and/or retinoid) or oral antibiotic + topical retinoid + BPO ± topical antibiotic.<sup>2</sup> Alternatives include a different combination therapy, a change of oral antibiotic, adding combined oral contraceptive or oral spironolactone (females), or oral isotretinoin.<sup>2</sup>

For severe acne, first-line recommendations are oral antibiotic + topical combination therapy (BPO + antibiotic and/or retinoid) or oral isotretinoin.<sup>2</sup> Alternatives are a change in oral antibiotic, adding combined oral contraceptive or oral spironolactone (females), or oral isotretinoin.<sup>2</sup>

Routine microbiological testing is not recommended for patients with acne, although those who exhibit acne-like lesions suggestive of Gram-negative folliculitis may benefit from microbiological testing.<sup>2</sup> Similarly, endocrinological evaluation (e.g., for androgen excess) is not generally recommended, although laboratory evaluation is recommended for patients with additional signs of androgen excess.

Oestrogen-containing combined oral contraceptives and spironolactone are recommended for inflammatory acne in select females.<sup>2</sup> Oral corticosteroids can also provide

temporary benefit in patients with severe inflammatory acne when starting standard acne treatment.<sup>2</sup> Low-dose oral corticosteroids are recommended for patients with well-documented adrenal hyperandrogenism.<sup>2</sup>

## Global Alliance Consensus

The most important of the Global Alliance Consensus recommendations are: a) that oral isotretinoin therapy should continue until full acne clearance; b) azelaic acid cream 20% or gel 15% can be used in pregnant women and patients with acne and PIH; c) early, effective treatment is important to minimise acne scarring; d) antibiotics (topical or systemic) should not be used as monotherapy; and e) maintenance therapy (topical retinoid ± BPO) should be used in most acne patients.<sup>3</sup>

According to acne severity/type, the Global Alliance Consensus recommends:<sup>3</sup>

- Mild comedonal acne: topical retinoid or fixed combination with retinoid > BPO or azelaic acid > salicylic acid.
- Mild papular/pustular acne: fixed combination or BPO or topical retinoid or azelaic acid.
- Moderate papular/pustular acne: a fixed combination is the preferred treatment ± hormonal therapy and/or oral antibiotic (particularly if the trunk is involved).
- Severe acne: a fixed combination + oral antibiotic is preferred; alternatives are to add oral isotretinoin or oral hormone therapy.
- Very severe nodular and/or conglobate acne:
  - Males: oral isotretinoin or fixed combination + oral antibiotics.
  - Females: oral isotretinoin + anti-androgenic hormonal therapy or fixed combination + oral antibiotics (possibly high dose) and/or oral anti-androgenic hormonal therapy are recommended.

Regardless of severity, if the patient responds they should be treated until classified as clear or almost clear, and topical retinoid ± BPO can be used as maintenance therapy.<sup>3</sup> If response is poor, various actions can be taken, including checking for non-drug-related problems (e.g., seborrhoea, stress, diet, comedogenic skin care products), considering treatment modifications, checking adherence, and asking about adverse events.<sup>3</sup>

## Gaps Between Guidelines and Clinical Practice

Adherence is essential for the success of acne treatment, and poor adherence has been correlated with an inadequate response to therapy.<sup>4</sup> Once-daily formulations are a valuable tool for improving patient adherence.

Retinoids can be used for the treatment and prevention of acne scars due to their anti-inflammatory actions.<sup>4</sup>

Although no large, prospective, multicentre, randomised, double-blinded, controlled trials have compared acne chemical peels (to placebo or each other), chemical peels<sup>5</sup> (e.g., salicylic acid, pyruvic acid, glycolic acid) can be used to treat acne scars.<sup>4</sup> Similarly, clinical trials for the safety and efficacy of different light and laser sources/wavelengths and which types of lesions they improve are lacking. However, light and laser devices are potentially useful therapeutic alternatives.<sup>4,6</sup>

There are no guidelines for the use of dermocosmetics (e.g., detergents, moisturisers, absorbing sebum products, camouflage, UV filters) in the management of acne. However, this is a very important part of therapy, especially for managing side effects and improving compliance.<sup>7</sup> Dermocosmetic management can be used for the treatment of sunburn in acne patients, retinoid dermatitis, seborrhoea, and truncal acne.

There are no specific therapeutic guidelines for acne according to skin phototype. In skin of colour patients, inflammatory lesions can more easily promote the development of PIH, scarring, and keloids.<sup>8</sup> The higher the skin phototype, the more intense the pigmentation and scarring tend to be.<sup>8</sup> A more vigorous treatment of acne may minimise these complications in skin of colour patients.<sup>8</sup>

No specific dietary changes are recommended in the management of acne. However, in Prof Fabbrocini's clinic, they observed that high glycaemic index diets may be associated with resistant acne. In their subsequent study, they showed that metformin and a hypocaloric diet significantly improved acne among males with resistant acne and an altered metabolic profile compared with no intervention.<sup>9</sup>

Products with robust clinical efficacy and safety data for both facial and truncal acne are lacking, as are clinical guidelines for the treatment of truncal acne. This is difficult to treat, due to the large area involved and the difficulties of application.<sup>10</sup> There is therefore a need for specific formulations, dedicated application methods, and different indications on application frequency.

## Unmet Medical Needs in Acne

Doctor Linda Stein Gold

### Epidemiology of Acne

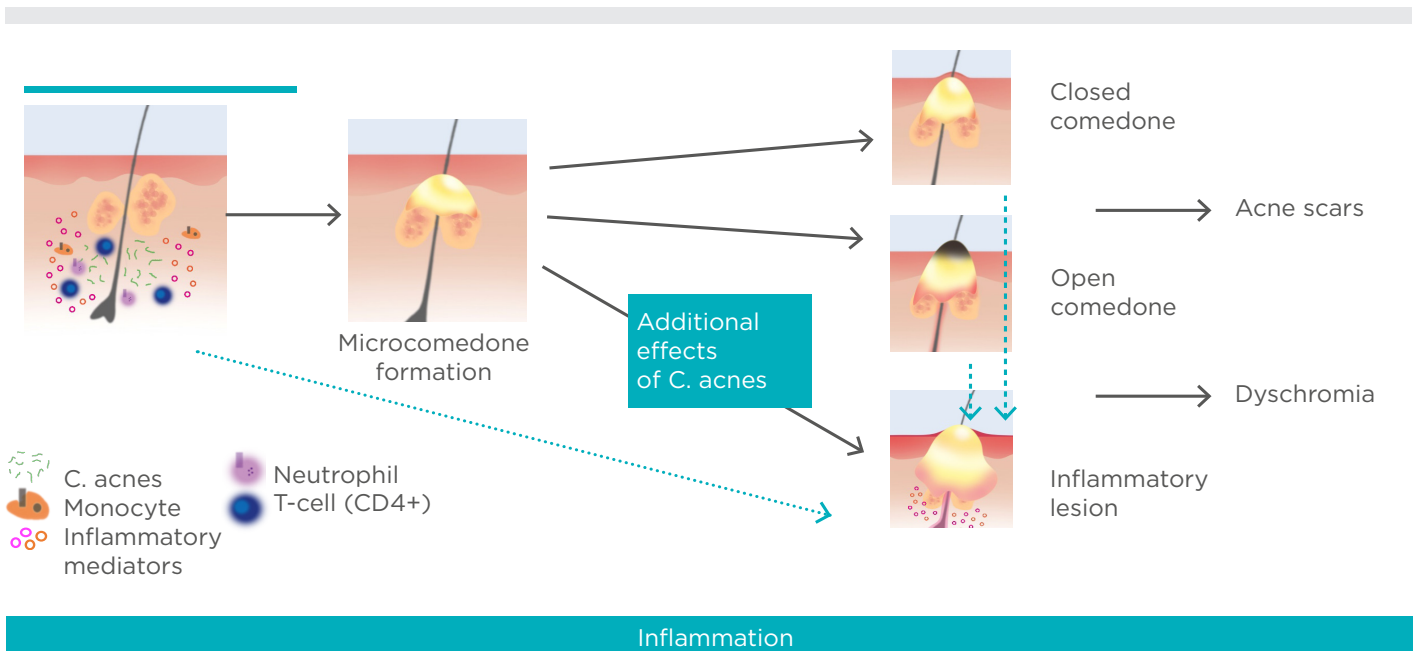
Acne vulgaris affects approximately 650 million people globally (>9% of the population)<sup>11</sup> and 40–50 million individuals in the USA.<sup>12</sup> It is the most common skin disorder to affect adolescents<sup>13</sup> and the most common skin disorder in the USA.<sup>14</sup>

### Pathogenesis of Acne

The understanding of the pathogenesis of acne continues to evolve. Put simply, it involves the interplay of four main factors: a) alteration in the keratinisation process; b) increased sebum

production (or altered sebum composition); c) *C. acnes* proliferation; and d) release of inflammatory mediators into the skin.<sup>4</sup>

Traditionally, microcomedo formation under the skin was thought to be the first step in the development of an acne lesion.<sup>4,15</sup> It was thought that this could then develop into a closed comedo, an open comedo, or an inflammatory lesion.<sup>4,15</sup> However, an immunohistochemical study of uninvolved skin and early inflamed lesions from patients with acne showed that subclinical inflammation precedes the formation of the microcomedo and that inflammatory lesions can arise from clinically normal skin.<sup>16</sup> Further, inflammatory dyschromias can persist even once lesions have resolved clinically, and inflammatory infiltrates can also be found in acne scars.<sup>17–19</sup> Therefore, an emerging view of lesion progression in acne vulgaris may be as shown in **Figure 1**.<sup>4,16,17,20</sup> Inflammation may occur before formation of the microcomedo, in which case subdividing acne into inflammatory and non-inflammatory would be a misnomer. This also highlights the importance of both early treatment and continuing treatment throughout the course of the acne lesions.



**Figure 1: Emerging view of lesion progression in acne vulgaris.**

*C. acnes*: Cutibacterium acnes.

Adapted from Thiboutot et al.,<sup>4</sup> Jeremy et al.,<sup>16</sup> McInturff and Kim,<sup>20</sup> and Do et al.<sup>17</sup>

## Acne Scarring

Acne and acne scarring can have a huge impact on patient quality of life. They can affect self-image, self-esteem, psychological well-being, and employability, and can result in anxiety, depression, anger, embarrassment, and humiliation.<sup>21-26</sup> However, treating acne scars is difficult for physicians and patients.<sup>25,27</sup>

Acne scarring affects both sexes and can occur with any severity of acne, but is more likely among those with more severe acne.<sup>25,28</sup> It occurs in approximately 25%, 50%, and 75% of patients with mild, moderate, and severe acne, respectively.<sup>29</sup> As the degree of scarring has been shown to increase significantly with longer duration of acne before adequate treatment,<sup>25</sup> early treatment of acne is essential.

A key study has recently analysed the pathogenesis of acne scars.<sup>30</sup> The researchers reported that 83% of persisting scars formed from post-inflammatory lesions, 16% from papules, and only 1% each from closed comedones or pustules.<sup>30</sup> The mean time from primary lesion to scar occurrence was 33 days, and scars were more likely after longer-lasting lesions.<sup>30</sup> Importantly, scars arose from superficial inflammatory acne lesions, not just nodulocystic acne. This study highlights the need for the early treatment of any kind of acne to prevent scarring.

## Acne in Skin of Colour

PIH (a darkened area of skin following trauma or cutaneous inflammation following acne) results from an abnormal release or overproduction of melanin.<sup>31</sup> PIH affects African Americans and Hispanic people more often than Caucasians (65% and 48% versus 25%, respectively, in a study of nearly 3,000 females aged 10-70 years).<sup>32</sup> PIH can also be more distressing for people with darker versus lighter skin,<sup>31,33,34</sup> and these dark patches can persist for years.<sup>34</sup>

## Adult Acne

Although adolescent acne affects more boys than girls, adult acne has been found to be significantly more common among women than men.<sup>35</sup> Most adult acne sufferers also had acne in their adolescence, but around 20% have late-onset acne.<sup>36</sup>

Traditionally, adult acne was thought to affect the U-zone (jawline, chin, neck), and it was believed that adults had more inflammatory lesions than adolescents.<sup>35-37</sup> However, in a study of 374 women (aged 25-66 years) with acne, 89.8% had facial acne involving multiple facial zones, 76.5% had mixed facial acne (inflammatory and non-inflammatory lesions), and only 11.2% had acne localised to the mandibular region.<sup>38</sup> Another study found that adult women (N=208) self-reported prominent areas of acne on the cheeks (79.8%), forehead (77.4%), nose (50.0%), and hairline (47.6%), as well as the 'traditional' jawline (61.5%) and chin (77.9%).<sup>39</sup>

## Truncal Acne

Approximately 50-60% of facial acne sufferers also have truncal acne,<sup>38,40,41</sup> while only ~2% of people have truncal lesions alone.<sup>40</sup> Truncal acne can affect many areas, most commonly the back, chest, and shoulders, but it can also affect the neck.<sup>38</sup> However, most patients with both facial and truncal acne do not mention their truncal acne. Despite this, many still expect their physicians to treat their unmentioned truncal acne.<sup>40</sup>

In a study of 2,201 18-year-old men entering the Brazilian military, 89.4% had acne.<sup>42</sup> Among those with inflammatory lesions (n=1,497), their backs were more commonly affected than their anterior chests (40.0% versus 4.4%). Similarly, among those with comedonal acne (n=1,487), their backs were more commonly affected than their anterior chests (17.9% versus 5.6%).<sup>42</sup>

Unfortunately, current guidelines contain little specific advice for treating truncal acne.<sup>1-3</sup> There is also a lack of products demonstrating robust clinical efficacy data for both the face and trunk.

## Emerging Treatments

Fortunately, there is a promising pipeline of treatments to tackle the challenges of acne scars, acne in skin of colour, adult female acne, and truncal acne, and these are discussed in the following section.

## Current and Emerging Treatments for Unmet Needs in Acne

Professor Jerry Tan

### Post-Inflammatory Hyperpigmentation

PIH, also known as macular erythema or macular pigmentation, can be particularly problematic in people with skin of colour. One of the first studies that specifically addressed this issue randomised 68 people with PIH (91% due to acne) and skin of colour to tretinoin 0.1% cream or vehicle nightly for 40 weeks.<sup>43</sup> In this double-blinded trial, which 54 patients completed, tretinoin resulted in significantly more patients achieving 'much lighter' PIH lesions than vehicle (58% versus 7%;  $p < 0.001$ ) at 40 weeks, with improvements noted after 4 weeks.<sup>43</sup> However, retinoid dermatitis developed in half of the patients.

Azelaic acid 15.0% gel twice daily has been evaluated in a small open-label, 16-week study of 20 patients with darker skin (phototypes IV–VI), mild-moderate acne, and moderate-severe PIH.<sup>44</sup> Among 13 patients with data at 16 weeks, most achieved  $\geq 2$ -grade improvement in acne (85%) and  $\geq 1$ -grade improvement in PIH (100%) severity, with 69% being clear of acne and 31% being clear of PIH.<sup>44</sup> However, azelaic acid can cause a burning tingling sensation in some patients.

A recent post-hoc subgroup analysis compared dapsone 7.5% gel by phototype (I–III versus IV–VI) among 4,327 patients aged  $\geq 12$  years with moderate acne from two Phase III, multicentre, randomised, double-blind, vehicle-controlled studies.<sup>45</sup> Patients in both phototype skin groups achieved significant improvements in their acne as early as 4 weeks ( $p < 0.001$ ), with little difference by skin phototype.<sup>45</sup> Stinging/burning, scaling, dryness, and erythema was mainly reported as 'none' or 'mild', again with little difference by skin phototype.<sup>45</sup>

### Adult Female Acne

Dapsone 5.0% gel twice daily has been tested in an open-label, 12-week study in 68 adult females with acne and skin of colour (phototypes IV–VI).<sup>46</sup> At the end of the study, 43% were rated as 'clear/almost clear' and there were no treatment-related adverse events.<sup>46</sup>

In an investigator-blinded study, 55 adult females with mild-moderate acne were randomised to azelaic acid 15.0% gel twice daily for 9 months or 3 months, or adapalene 0.1% gel once daily for 9 months.<sup>47</sup> The mean number of inflammatory lesions decreased from approximately 20 at baseline to around 12 at 12 weeks in all three groups.<sup>47</sup> This was maintained through 36 weeks among those randomised to 9 months of either treatment, while among those who stopped azelaic acid after 3 months, the mean inflammatory lesion count increased gradually to 16.<sup>47</sup> In terms of tolerability, there was significantly more dryness and scaling with adapalene than azelaic acid at 6 and 12 weeks ( $p < 0.05$ ).<sup>47</sup>

In a retrospective study of 70 adult females with acne, spironolactone  $\leq 150$  mg/day was associated with reductions in facial inflammatory superficial and retentional (comedonal) lesions after 6 and 12 months.<sup>48</sup> A recent hybrid systematic review reported that high-dose spironolactone (200 mg per day) significantly reduces inflammatory lesion counts and that side effects are related to dose (particularly menstrual irregularities).<sup>49</sup> However, the evidence was rated as low or very low quality.<sup>49</sup> The review also reported that routine potassium monitoring is largely unnecessary,<sup>49</sup> but Prof Tan added that this is required among patients with type 4 renal tubular acidosis.

### Acne Scarring

In a small, open-label study, 20 patients with moderate-severe facial atrophic acne scars (Goodman-Baron grade 3/4 or  $\geq 5$  atrophic scars) but no active acne received adapalene 0.3% gel once daily for 4 weeks, then twice daily for 20 weeks.<sup>50</sup> Most patients (78%) achieved moderate/complete improvements in Investigator's Global Assessment (IGA) of atrophic acne scar severity, with the other 22% achieving slight improvement.<sup>50</sup> Importantly, immunohistochemical studies showed 58% and 15% increases in collagen-3 and procollagen-1, respectively.<sup>50</sup>

In a recent investigator-blinded, randomised study, 31 patients with moderate facial acne and  $\geq 10$  atrophic scars applied adapalene 0.1%/BPO 2.5% gel to one side of their face and vehicle to the other side once daily for 6 months.<sup>51</sup> Mean acne scar count increased in the vehicle side of the face (from 10.9 to 13.6), but not in the treated

side (from 11.1 to 11.6) ( $p=0.036$ ).<sup>51</sup> At baseline, only 9.7% of patients were rated 'almost clear' by Scar Global Assessment (SGA), but this increased to 45.2% with treatment (versus 6.5% with vehicle) at 6 months ( $p=0.0032$ ).<sup>51</sup>

Using a similar study design, 67 patients with moderate-severe facial acne were randomised to adapalene 0.3%/BPO 2.5% gel on one side of their face and vehicle on the other.<sup>52</sup> With this higher strength of adapalene, the mean number of scars decreased with treatment and increased with vehicle (Figure 2;  $p<0.001$ ).<sup>52</sup> After 24 weeks, significantly more treated face sides were assessed as 'clear/almost clear' by SGA compared with vehicle face sides (32.9% versus 16.4%;  $p<0.0001$ ).<sup>52</sup>

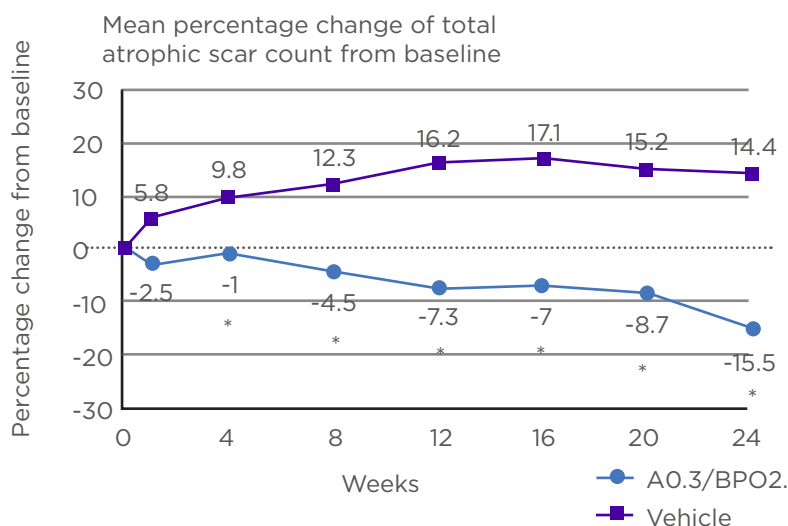
## Truncal Acne

In a small open-label study, 20 patients with moderate or worse truncal acne applied dapson 7.5% gel once daily for 16 weeks.<sup>53</sup> Although only 15 patients completed the study, the percentages with 2-grade improvement and rated 'clear/almost clear' by IGA increased to 5%, 25%, and 45% at 4, 10, and 16 weeks, respectively.<sup>53</sup>

Azelaic acid 15.0% foam twice daily has been tested in a small open-label, 16-week study of 20 patients with moderate or worse truncal acne.<sup>54</sup> The percentage of patients rated 'clear/almost clear' by IGA increased to 39% and 61% for facial acne at 8 and 16 weeks, respectively; and to 11% and 44%, respectively, for truncal acne.<sup>54</sup>

In a small study, 30 women aged 18-45 years with 10-50 truncal acne lesions were randomised to oral drospirenone 3 mg/ethinyl oestradiol 0.02 mg or placebo.<sup>55</sup> Among 25 women analysed, six cycles (24 days of treatment/placebo, 4 days of inert tablets) resulted in larger percentage reductions in non-inflammatory (52% versus -9%), inflammatory (53% versus 18%), and total lesion counts (57% versus 17%) with treatment versus placebo.<sup>55</sup>

In two Phase III, randomised trials, 2,420 patients with moderate acne vulgaris on the face and trunk were randomised to the new, selective retinoic acid receptor topical retinoid, trifarotene 50 µg/g cream, or vehicle.<sup>56</sup> IGA success (clear or almost clear and  $\geq 2$ -grade improvement) for facial acne was achieved in significantly more treated versus vehicle patients in PERFECT 1 (29.7% versus 20.0%; Figure 3A) and PERFECT 2 by 12 months (42.8% versus 25.8%; Figure 3B).<sup>56</sup>

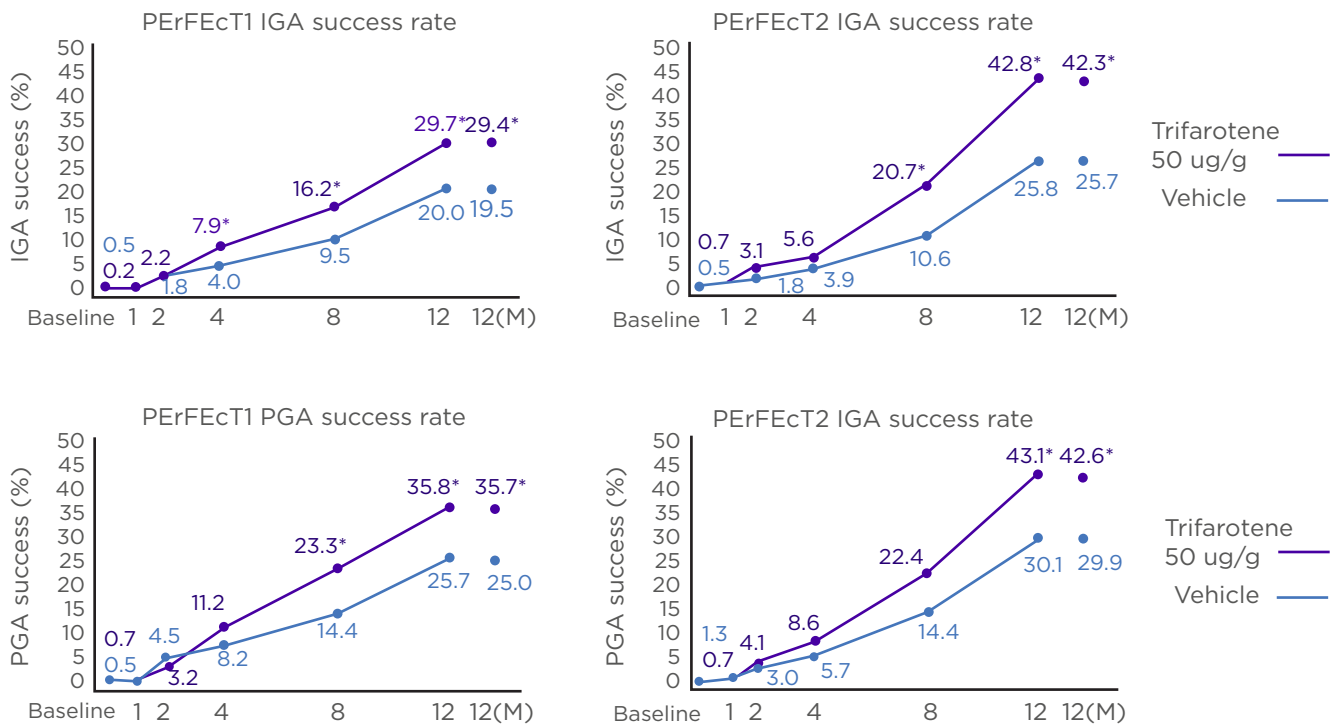


**Figure 2: Mean percentage change from baseline in total atrophic scar count with adapalene 0.3%/BPO 2.5% gel versus vehicle.**

A: adapalene; BPO: benzoyl peroxide.

\* $p<0.001$ .

Reproduced from Dréno et al.<sup>52</sup>



**Figure 3: IGA (facial) and PGA (truncal) success rates in the PERFECT 1 and 2 studies.**

IGA: Investigator's Global Assessment; MI: multiple imputation (for missing values); PGA: Physician's Global Assessment.

Reproduced from Tan et al.<sup>56</sup>

Similarly, Physician's Global Assessment (the truncal equivalent to the IGA) success for truncal acne was achieved in significantly more treated versus vehicle patients in PERFECT1 (35.8% versus 25.7%; **Figure 3C**) and PERFECT 2 (43.1% versus 30.1%; **Figure 3D**).<sup>56</sup> Local irritation (erythema, scaling, dryness, stinging/burning) was transient and mainly mild-moderate, and local tolerability was better on the trunk than the face.<sup>56</sup>

Trifarotene has also been tested in a longer-term (52-week), open-label, Phase III study in 453 patients.<sup>57</sup> Global success rates ('clear' or 'almost clear') were 65.1% for facial acne and 66.9% for truncal acne.<sup>57</sup> Mean tolerability scores were

<1 (i.e., mild) for local tolerability (erythema, dryness, scaling, stinging/burning) on the face and trunk at all time points, and decreased over time.<sup>57</sup> Tolerability was better on the trunk than the face.<sup>57</sup> Severe adverse events deemed related to study drug occurred in three patients (0.7%): irritation, pruritus, and erythema.<sup>57</sup> Serious adverse events occurred in 10 patients (2.2%), but none were considered related to study drug.<sup>57</sup> A total of 16 patients (3.5%) discontinued due to adverse events.<sup>57</sup> Of note, trifarotene is one of the first acne treatments that has had its safety and tolerability specifically tested for truncal acne in large-scale studies.

## References

- Nast A et al. European evidence-based (S3) guideline for the treatment of acne - update 2016 - short version. *J Eur Acad Dermatol Venereol.* 2016;30(8):1261-8.
- Zaenglein AL et al. Guidelines of care for the management of acne vulgaris. *J Am Acad Dermatol.* 2016;74(5):945-73.e33.
- Thiboutot DM et al. Practical management of acne for clinicians: An international consensus from the Global Alliance to Improve Outcomes in Acne. *J Am Acad Dermatol.* 2018;78(2 Suppl 1):S1-S23.e1.



4. Thiboutot D et al. New insights into the management of acne: An update from the Global Alliance to Improve Outcomes in Acne group. *J Am Acad Dermatol.* 2009;60(5 Suppl):S1-50.
5. Fabbrocini G et al. "Glycolic acid", A. Tosti, P. E. Grimes and M. P. De Padova (eds), *Color Atlas of Chemical Peels* (2012), Berlin Heidelberg: Springer-Verlag, pp. 9-16.
6. Nestor MS et al. The use of photodynamic therapy in dermatology: Results of a consensus conference. *J Drugs Dermatol.* 2006;5(2):140-54.
7. Araviiskaia E, Dreno B. The role of topical dermocosmetics in acne vulgaris. *J Eur Acad Dermatol Venereol.* 2016;30(6):926-35.
8. Taylor SC et al. Acne vulgaris in skin of color. *J Am Acad Dermatol.* 2002;46(2 Suppl Understanding):S98-106.
9. Fabbrocini G et al. Low glycaemic diet and metformin therapy: A new approach in male subjects with acne resistant to common treatments. *Clin Exp Dermatol.* 2016;41(1):38-42.
10. Del Rosso JQ. Truncal acne vulgaris: The relative roles of topical and systemic antibiotic therapy. *J Drugs Dermatol.* 2007;6(2):148-51.
11. Vos T et al. Years lived with disability (YLDs) for 1160 sequelae of 289 diseases and injuries 1990-2010: A systematic analysis for the Global Burden of Disease Study 2010. *Lancet.* 2012;380(9859):2163-96.
12. White GM. Recent findings in the epidemiologic evidence, classification, and subtypes of acne vulgaris. *J Am Acad Dermatol.* 1998;39(2 Pt 3):S34-7.
13. Lynn DD et al. The epidemiology of acne vulgaris in late adolescence. *Adolesc Health Med Ther.* 2016;713-25.
14. American Academy of Dermatology. Skin conditions by the numbers. Acne. Available at: <https://www.aad.org/media/stats/conditions/skin-conditions-by-the-numbers>. Last accessed: 12 June 2019.
15. Pochi PE. The pathogenesis and treatment of acne. *Annu Rev Med.* 1990;41:187-98.
16. Jeremy AH et al. Inflammatory events are involved in acne lesion initiation. *J Invest Dermatol.* 2003;121(1):20-7.
17. Do TT et al. Computer-assisted alignment and tracking of acne lesions indicate that most inflammatory lesions arise from comedones and de novo. *J Am Acad Dermatol.* 2008;58(4):603-8.
18. Vowels BR et al. Induction of proinflammatory cytokines by a soluble factor of *Propionibacterium acnes*: Implications for chronic inflammatory acne. *Infect Immun.* 1995;63(8):3158-65.
19. Lee WJ et al. Serial sections of atrophic acne scars help in the interpretation of microscopic findings and the selection of good therapeutic modalities. *J Eur Acad Dermatol Venereol.* 2013;27(5):643-6.
20. McInturff JE, Kim J. The role of toll-like receptors in the pathophysiology of acne. *Semin Cutan Med Surg.* 2005;24(2):73-8.
21. Cotterill JA, Cunliffe WJ. Suicide in dermatological patients. *Br J Dermatol.* 1997;137(2):246-50.
22. Gupta MA, Gupta AK. Depression and suicidal ideation in dermatology patients with acne, alopecia areata, atopic dermatitis and psoriasis. *Br J Dermatol.* 1998;139(5):846-50.
23. Lasek RJ, Chren MM. Acne vulgaris and the quality of life of adult dermatology patients. *Arch Dermatol.* 1998;134(4):454-8.
24. Dalgard F et al. Self-esteem and body satisfaction among late adolescents with acne: Results from a population survey. *J Am Acad Dermatol.* 2008;59(5):746-51.
25. Layton AM et al. A clinical evaluation of acne scarring and its incidence. *Clin Exp Dermatol.* 1994;19(4):303-8.
26. Cunliffe WJ. Acne and unemployment. *Br J Dermatol.* 1986;115(3):386.
27. Kang S et al. Inflammation and extracellular matrix degradation mediated by activated transcription factors nuclear factor-kappaB and activator protein-1 in inflammatory acne lesions in vivo. *Am J Pathol.* 2005;166(6):1691-9.
28. Tan JK et al. Development and validation of a Scale for Acne Scar Severity (SCAR-S) of the face and trunk. *J Cutan Med Surg.* 2010;14(4):156-60.
29. Dreno B et al. Evaluation of the prevalence, risk factors, clinical characteristics, and burden of acne scars among active acne patients in Brazil, France, and the USA [abstract 5616]. *J Am Acad Dermatol.* 2017;76(6 Suppl 1):AB132.
30. Tan J et al. Prospective study of pathogenesis of atrophic acne scars and role of macular erythema. *J Drugs Dermatol.* 2017;16(6):566-72.
31. Callender VD et al. Racial differences in clinical characteristics, perceptions and behaviors, and psychosocial impact of adult female acne. *J Clin Aesthet Dermatol.* 2014;7(7):19-31.
32. Perkins AC et al. Comparison of the epidemiology of acne vulgaris among Caucasian, Asian, Continental Indian and African American women. *J Eur Acad Dermatol Venereol.* 2011;25(9):1054-60.
33. Gorelick J et al. Acne-related quality of life among female adults of different races/ethnicities. *J Dermatol Nurses Assoc.* 2015;7(3):154-62.
34. Yin NC, McMichael AJ. Acne in patients with skin of color: Practical management. *Am J Clin Dermatol.* 2014;15(1):7-16.
35. Collier CN et al. The prevalence of acne in adults 20 years and older. *J Am Acad Dermatol.* 2008;58(1):56-9.
36. Holzmann R, Shakery K. Postadolescent acne in females. *Skin Pharmacol Physiol.* 2014;27(Suppl 1):3-8.
37. Fisk WA et al. Epidemiology and Management of Acne in Adult Women. *Curr Dermatol Rep.* 2014;3(1):29-39.
38. Dreno B et al. Large-scale international study enhances understanding of an emerging acne population: Adult females. *J Eur Acad Dermatol Venereol.* 2015;29(6):1096-106.
39. Tanghetti EA et al. Understanding the burden of adult female acne. *J Clin Aesthet Dermatol.* 2014;7(2):22-30.
40. Del Rosso JQ et al. A closer look at truncal acne vulgaris: Prevalence, severity, and clinical significance. *J Drugs Dermatol.* 2007;6(6):597-600.
41. Tan JK et al. Prevalence and severity of facial and truncal acne in a referral cohort. *J Drugs Dermatol.* 2008;7(6):551-6.
42. Duquia RP et al. Most common patterns of acne in male adolescents: A population-based study. *Int J Dermatol.* 2013;52(5):550-3.
43. Bulengo-Ransby SM et al. Topical tretinoin (retinoic acid) therapy for hyperpigmented lesions caused by inflammation of the skin in black patients. *N Engl J Med.* 1993;328(20):1438-43.
44. Kircik LH. Efficacy and safety of azelaic acid (Aza) gel 15% in the treatment of post-inflammatory hyperpigmentation and acne: A 16-week, baseline-controlled study. *J Drugs Dermatol.* 2011;10(6):586-90.
45. Taylor SC et al. Efficacy, safety, and tolerability of topical dapsone gel, 7.5% for treatment of acne vulgaris by Fitzpatrick Skin Phototype. *J Drugs Dermatol.* 2018;17(2):160-7.
46. Alexis AF et al. The efficacy and safety of topical dapsone gel, 5% for the treatment of acne vulgaris in adult females with skin of color. *J Drugs Dermatol.* 2016;15(2):197-204.
47. Thielitz A et al. A randomized investigator-blind parallel-group study to assess efficacy and safety of azelaic acid 15% gel vs. adapalene 0.1% gel in the treatment and maintenance treatment of female adult acne. *J Eur Acad Dermatol Venereol.* 2015;29(4):789-96.
48. Isvy-Joubert A et al. Adult female acne treated with spironolactone: A retrospective data review of 70 cases.

- Eur J Dermatol. 2017;27(4):393-8.
49. Layton AM et al. Oral spironolactone for acne vulgaris in adult females: A hybrid systematic review. *Am J Clin Dermatol*. 2017;18(2):169-91.
  50. Loss MJ et al. Adapalene 0.3% gel shows efficacy for the treatment of atrophic acne scars. *Dermatol Ther (Heidelb)*. 2018;8(2):245-57.
  51. Dreno B et al. Adapalene 0.1%/benzoyl peroxide 2.5% gel reduces the risk of atrophic scar formation in moderate inflammatory acne: A split-face randomized controlled trial. *J Eur Acad Dermatol Venereol*. 2017;31(4):737-42.
  52. Dreno B et al. Prevention and reduction of atrophic acne scars with adapalene 0.3%/benzoyl peroxide 2.5% gel in subjects with moderate or severe facial acne: Results of a 6-month randomized, vehicle-controlled trial using intra-individual comparison. *Am J Clin Dermatol*. 2018;19(2):275-86.
  53. Del Rosso JQ et al. Management of truncal acne vulgaris with topical dapsone 7.5% gel. *J Clin Aesthet Dermatol*. 2018;11(8):45-50.
  54. Hoffman LK et al. The efficacy and safety of azelaic acid 15% foam in the treatment of truncal acne vulgaris. *J Drugs Dermatol*. 2017;16(6):534-8.
  55. Palli MB et al. A single-center, randomized double-blind, parallel-group study to examine the safety and efficacy of 3mg drospirenone/0.02 mg ethinyl estradiol compared with placebo in the treatment of moderate truncal acne vulgaris. *J Drugs Dermatol*. 2013;12(6):633-7.
  56. Tan J et al. Randomized phase 3 evaluation of trifarotene 50 mug/g cream treatment of moderate facial and truncal acne. *J Am Acad Dermatol*. 2019;80(6):1691-9.
  57. Blume-Peytavi U et al. Long-term safety and efficacy of trifarotene 50mug/g cream, a first-in-class RAR-gamma selective topical retinoid, in patients with moderate facial and truncal acne. *J Eur Acad Dermatol Venereol*. 2019. [Epub ahead of print].